

## Case Report: Myiasis due to *Cochliomyia hominivorax* and *Dermatobia hominis*: Clinical and Pathological Differences between Two Species in Northern Peru

Virgilio E. Failoc-Rojas,<sup>1,2,4\*</sup> Carolina Molina-Ayasta,<sup>2</sup> Jaime Salazar-Zuloeta,<sup>1</sup> Abel Samamé,<sup>3</sup> and Heber Silva-Díaz<sup>4</sup>

<sup>1</sup>School of Medicine, Universidad Nacional Pedro Ruiz Gallo, Lambayeque, Peru; <sup>2</sup>Centro de Epidemiología Clínica y Medicina Basada en Evidencias, Universidad San Martín de Porres, Lambayeque, Peru; <sup>3</sup>Laboratorio de Neurociencia y Comportamiento, Universidad Peruana Cayetano Heredia, Lima, Peru;

<sup>4</sup>Laboratorio de Parasitología, Metaxénicas y Zoonosis, Hospital Regional Lambayeque, Lambayeque, Peru

**Abstract.** Infestations caused by fly larvae (Myiasis) have been observed in patients with risk factors and in tropical zones. The aim of our study was to describe the clinical and epidemiological aspects and the risk factors associated with the occurrence of obligatory myiasis, as well as the therapeutic approach to patients. We identified the cases of myiasis diagnosed in two referral hospitals in northern Peru from January 2012 to December 2015 and included patients in whom larval development and a compatible clinical profile were observed. Epidemiological, clinical, analytical, diagnostic, therapeutic, and follow-up data were collected from clinical files. Nine clinical cases were compatible with a diagnosis of myiasis; of these, two were pediatric patients, one was a middle-aged adult, and six were elderly patients. Four of the nine patients were male. The identified species were *Dermatobia hominis* and *Cochliomyia hominivorax*. The therapeutic approach included antiparasitic therapy with ivermectin, antibacterial, and in some cases, anti-inflammatory drugs. *Dermatobia hominis* and *C. hominivorax* are the predominant species causing myiasis in northern Peru.

### INTRODUCTION

Myiasis is the development of fly larvae that infest the skin, necrotic tissues, and natural cavities in living persons.<sup>1–3</sup> The fly larvae belong to the order Diptera, class Insecta,<sup>1</sup> and the species vary depending on the geographic area. Myiasis cases are classified into three categories, depending on the causative agent: obligatory myiasis, caused by *Dermatobia hominis*, *Cochliomyia hominivorax*, *Cordylobia*, *Oestrus ovis*, *Wohlfahrtia magnifica*, or *Hypoderma bovis*<sup>1–4</sup>; facultative myiasis, by *Calliphora vicina*, *Phaenicia sericata*, *Lucilia illustris*, or *Sarcophaga haemorrhoidalis*; and accidental myiasis, by *Musca domestica*, *Drosophila* sp., *Chrysomya albiceps*, *Eristalis tenax*, *Piophilidae casei*, among others.<sup>4–8</sup>

Factors contributing to the development of human myiasis include low socioeconomic status, unhealthy environment, alcoholism, neurological disease, lack of personal hygiene, presence of varicose ulcers, advanced stages of cancer, malnutrition, immunosuppression, sexually transmitted diseases, diabetes, oral cavity lesions, advanced age, and animal husbandry.<sup>5–7</sup>

Human myiasis has been reported on a few occasions in Peru. Beltran<sup>9</sup> reported three cases of ophthalmomyiasis by *O. ovis*, whereas Miranda<sup>10</sup> described cutaneous myiasis by *C. hominivorax* (five cases) and *Stomoxys calcitrans* (one case); on the other hand, Espinoza<sup>3</sup> reported an oral myiasis by *C. hominivorax*. However, this infestation has been poorly studied in this country. It can occur in various ways, with different levels of severity and a difficult therapeutic approach. In this regard, the aim of our study was to describe the clinical and epidemiological aspects and the risk factors associated with obligatory myiasis (one of the most frequently reported in Peru), as well as its therapeutic approach.

### METHODS

A retrospective study was performed on all patients admitted with a confirmed diagnosis of myiasis (CIE-10: B87) at

Hospital Regional Lambayeque and Hospital Nacional Almanzor Aguinaga Asenjo (both category III hospitals) from January 2012 to December 2015. The diagnosis was made on clinical presentation, removal of larvae, and evidence of larval development and morphology.

Clinical (disease duration, type of presentation, signs, and symptoms), epidemiological (place of origin), therapeutic (drugs used), and follow-up data were collected from patients' medical histories (age, gender, and comorbidities), and identification of each type of myiasis was based on the larval morphology (tracheal trunks, dorsum, etc.), as described in literature<sup>8</sup>; briefly, different larval specimens were collected into saline and sent to the Laboratory of Parasitology of the Hospital Regional Lambayeque for entomologic identification by taxonomic keys that emphasize certain morphological features<sup>8</sup> (Figure 1). The study protocol was approved by the ethics committee of Hospital Regional Lambayeque. The authors claim to respect the confidentiality of the data and the protection of anonymity of patients.

### RESULTS

As shown in Table 1, in this retrospective study we reported nine clinical cases compatible with the diagnosis of myiasis, which were categorized into age groups: pediatric (two cases; mean age of 3 years), middle-aged adults (one 52-year-old case), and elderly patients (six cases; mean age of 73.5 years). Four of these cases were male, and patients' interviews revealed that only four of nine cases were contracted in the tropical rain forest, whereas the others were from the coastal area of Peru.

We reported five cases of myiasis caused by *C. hominivorax*, and four cases caused by *D. hominis*. Of the five cases caused by *C. hominivorax*, four were related to comorbidities such as cancer (invasive squamous cell carcinoma, laryngeal cancer, squamous cell carcinoma, and breast cancer), whereas the remaining case had a clinical history of tuberculosis. On the other hand, two of the infestations caused by *D. hominis* were pediatric cases without established comorbidities.

In one case (nasal myiasis), the larva was asphyxiated with *Ocimum basilicum* "basil," manually removed, and then the

\* Address correspondence to Virgilio E. Failoc-Rojas, Av. Manuel Seoane, 1343-La Victoria, Chiclayo, Peru. E-mail: virgiliofr@gmail.com

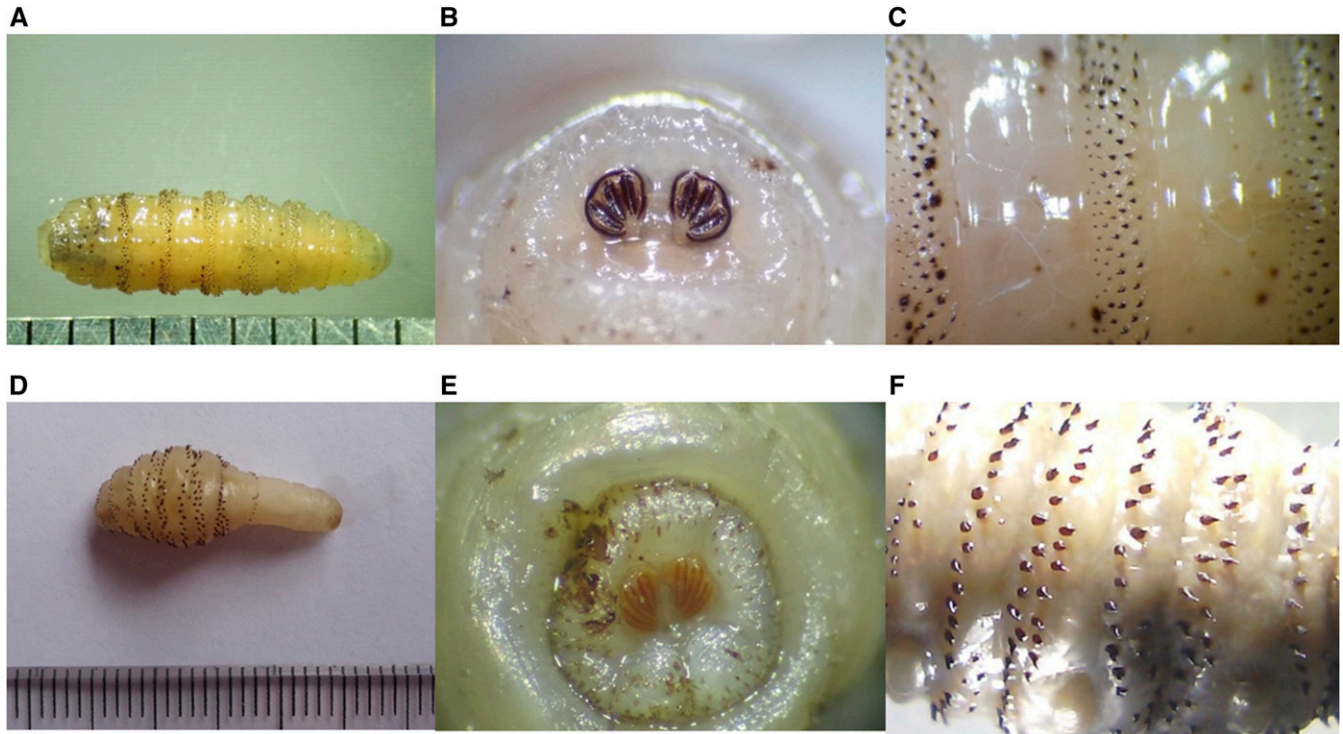


FIGURE 1. Top: Third-instar larva of *Cochliomyia hominivorax*: (A) Dorsal view showing the pigmented dorsal tracheal trunks, visible in the last four body segments; (B) Posterior spiracles with three straight grooves on each and open peritremes; (C) Segments with bands of small cuticular spines. Bottom: Third-instar larva of *Dermatobia hominis*. (D) Dorsal view showing a narrow rear end without cuticular spines in the last three segments; (E) Posterior spiracles with three straight grooves on each and peritremes; (F) Segments with rows of prominent cuticular spines. This figure appears in color at [www.ajtmh.org](http://www.ajtmh.org).

patient received antibiotic treatment. The therapeutic approach to myiasis varied among the cases; however, antibacterial (beta lactams and quinolones), antiparasitic (ivermectin), and anti-inflammatory therapy were common. In some cases by *C. hominivorax*, surgical cleansing was used. See additional details in Table 1.

#### DISCUSSION

This report discloses a series of myiasis cases by two obligate parasites, *C. hominivorax* and *D. hominis*, from two referral hospitals in the northern macro region of Peru in recent years (2012–2015).

Human myiasis remains a neglected disease, i.e., poorly studied and not adequately treated by health authorities; however, a number of cases with difficult approaches have been reported, from oral,<sup>3</sup> cutaneous,<sup>4</sup> ophthalmomyiasis,<sup>9</sup> tracheostomal,<sup>11</sup> to nosocomial<sup>12</sup> myiasis. Frequent complications are bacterial superinfection that causes septicemia, tetanus,<sup>7</sup> and cerebral myiasis causing death.<sup>13</sup>

In this study, we report cases of cutaneous, scalp, nasal, and tracheostomal myiasis, all of positive clinical course but with high symptoms. Patients with myiasis caused by *D. hominis* had severe pain, phlogosis in skin lesions, active bleeding, and cutaneous abscesses, whereas in the cases caused by *C. hominivorax*, patients had a history of tuberculosis, squamous cell carcinoma, or laryngeal or breast cancer.

All the cases of cutaneous myiasis caused by *D. hominis* were contracted in areas with tropical climates, all with a

history of insect bite, which subsequently showed phlogosis signs in the wound; this is compatible with the clinical and life cycle of this type of Diptera.<sup>1,4,7</sup> On the other hand, the myiasis caused by *C. hominivorax* affected patients with old, necrotic, and exposed skin lesions, such as squamous cell carcinomas or tracheostomy patients; i.e., unlike the life cycle of *D. hominis* (Figure 2), it did not require a vector for the development of myiasis, merely an exposed wound.

Because *D. hominis* is transmitted by mosquitoes or other hematophagous arthropods, it causes problems for people living in tropical areas, where these vectors, which carry the larval eggs on their bodies to the host, abound. By contrast, *C. hominivorax*, whose transmission is direct, could present a wider geographical distribution in the northern regions of Peru.<sup>2,3,5</sup>

As shown by our data, this parasitic infestation mostly affected either elderly or very young patients. Interestingly, children were most commonly infested by *D. hominis*,<sup>4</sup> whereas adults (with comorbidities of necrosis such as cancer and tuberculosis) were most affected by *C. hominivorax*.<sup>3,5,6,11</sup>

In this context, myiasis must be managed by the authorities as a sanitary problem in this region. Furthermore, public policies in animal health are also necessary for the management of myiasis in the agricultural field as domestic and wild animals are reservoirs of this disease<sup>13,14</sup> and tourism to endemic areas has become increasingly common.<sup>15</sup> Finally, the diagnosis of myiasis is clinical and epidemiological, and should be duly recognized in health care centers for suitable treatment and control.

TABLE 1  
Summary of treatment, epidemiological, and clinical features of myiasis patients treated in Lambayeque, Peru

Case	Age (gender)	Patient comorbidities	Description	Injury features	Received treatment	Isolated species
1	74 (M)	Uncontrolled hypertension	Presented a snakebite on the right foot 5 days before symptoms	Two phlogotic and furunculoid nodules with small pores on the right foot, where movement of larvae was observed by ultrasound	Ciprofloxacin 200 mg. IV every 12 hour Oxacillin 2 g. IV every 4 hour Chlorphenamine 4 mg. 1 tab. PO	<i>Dermatobia hominis</i>
2	52 (F)	None	Presented an insect bite on the buttock and, a month later, a local abscess was observed	Painful bleeding boil-like lesion on buttock The diagnosis was made by ultrasound; lesions (3 mm) with surrounding edema (8–10 mm) and larvae were observed	Cefazolin 500 mg. IV every 8 hour Glucose 5 x 1,000 mL Mupirocin ointment in ampule applied twice a day	<i>Dermatobia hominis</i>
3	2 (F)	Prematurity, low psychomotor development	Presented an insect bite on the buttock a month before hospitalization	Painful abscess (2 by 2 cm) on the buttock with excoriation and larvae emerging from the lesion	Cefazolin 300 mg. IV every 8 hour for 11 days Ivermectin 9 drops (single dose)	<i>Dermatobia hominis</i>
4	71 (M)	Invasive squamous cell carcinoma of the distal phalanx	Treated for an increase of the skin eruption on the left foot	Phlogotic and erythematous skin eruption on the fifth toe of the left foot	Drainage by surgery Exeresis of the toe of the infiltrated foot Cefazolin 1 g Gentamicin 80 g. IV every 8 hour	<i>Cochliomyia hominivorax</i>
5	4 (M)	None	Presented an erythematous and pruritic scalp lesion a month before	Scabby lesion (3 by 2 cm) with purulent discharge on the frontal region	Hydroxyzine 15 days Ivermectin single dose	<i>Dermatobia hominis</i>
6	71 (F)	History of tuberculosis	Facial cellulite; anterior epistaxis and referred nasal pain.	Nasal pain; respiratory distress and epistaxis.	Ciprofloxacin 200 mg. IV every 12 hour Clindamycin 600 mg. IV every 8 hour	<i>Cochliomyia hominivorax</i>
7	67 (F)	Laryngeal cancer (III)	Tracheostomy due to respiratory distress	Presence of larvae in the place of tracheostomy; cervical abscess surrounded by necrotic tissue, brown discharge, and traces of blood	Ivermectin 14 mg. (60 drops) PO, ceftriaxone 2 g/day PO and metronidazole 500 mg. IV every 8 hour	<i>Cochliomyia hominivorax</i>
8	85 (M)	Arterial hypertension; squamous cell carcinoma; nasal inverted papilloma and history of nasal myiasis	History of nasal polyps (surgically intervened three times); necrotic lesion on the upper third of the nose	Presence of larvae in the necrotic area on the upper third of the nose; intense pain	Ivermectin 3 mg, two tablets in 2 days; surgical cleansing Ceftazidime 1 g twice/day for 3 days	<i>Cochliomyia hominivorax</i>
9	73 (F)	Invasive left breast cancer (III) Diabetes mellitus II	Ulcerated lesion with necrosis, irregular borders and phlogosis on nipple; serosanguineous discharge and larvae emerging from the lesion	Presence of larvae in the lesion and necrotic area on the left breast; itching and pain	Ivermectin 14 mg (60 drops) PO for 2 days Ciprofloxacin 200 mg. IV every 12 hour Clindamycin 600 mg. IV every 8 hour	<i>Cochliomyia hominivorax</i>

M = male; F = female. All cases progressed favorably during hospitalization.

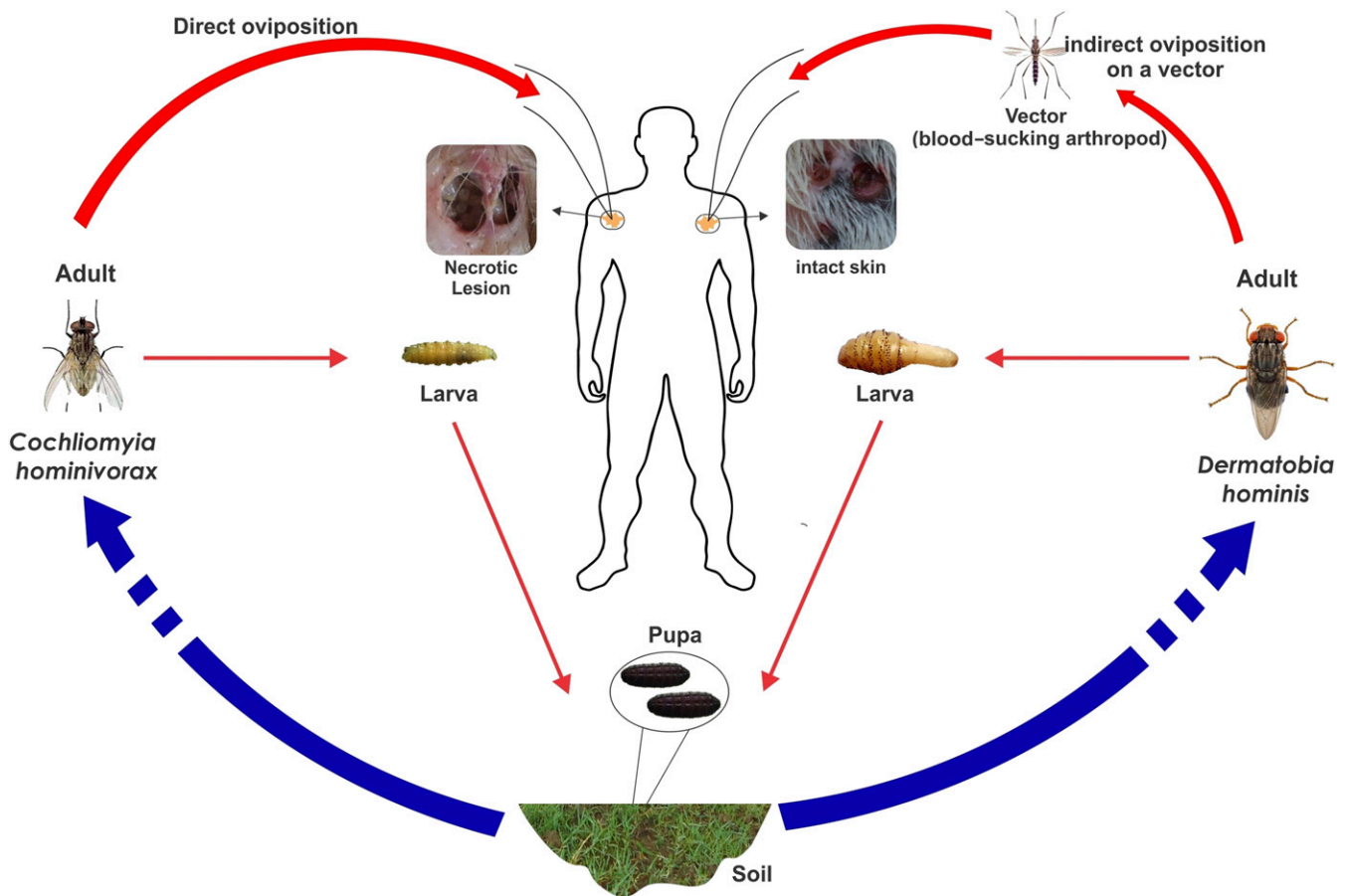


FIGURE 2. Cycle according to the type of myiasis: *Cochliomyia hominivorax* and *Dermatobia hominis*. This figure appears in color at [www.ajtmh.org](http://www.ajtmh.org).

Received June 2, 2016. Accepted for publication July 6, 2017.

Published online November 20, 2017.

Acknowledgments: We thank Suzanna Rojas Thompson for her constructive comments on an earlier version of this manuscript and Boris Castañeda for his help with graphics and designs.

Authors' addresses: Virgilio E. Failoc-Rojas, School of Medicine, Universidad Nacional Pedro Ruiz Gallo, Lambayeque, Peru, and Laboratorio de Parasitología, Metaxénicas y Zoonosis, Hospital Regional Lambayeque, Lambayeque, Peru, E-mail: [virgiliofr@gmail.com](mailto:virgiliofr@gmail.com). Carolina Molina-Ayasta, School of Medicine, Universidad San Martín de Porres, Lambayeque, Peru, E-mail: [caritomolinaayasta@gmail.com](mailto:caritomolinaayasta@gmail.com). Jaime Salazar-Zuloeta, School of Medicine, Universidad Nacional Pedro Ruiz Gallo, Lambayeque, Peru, E-mail: [jaimosalazarzuloeta@yahoo.es](mailto:jaimosalazarzuloeta@yahoo.es). Abel Samamé, Laboratorio de Neurociencia y Comportamiento, Universidad Peruana Cayetano Heredia, Lima, Peru, E-mail: [abel.samame@neurocienciaperu.org](mailto:abel.samame@neurocienciaperu.org). Heber Silva-Díaz, Laboratorio de Parasitología, Metaxénicas y Zoonosis, Hospital Regional Lambayeque, Lambayeque, Peru, E-mail: [h.silvadiaz@hotmail.com](mailto:h.silvadiaz@hotmail.com).

## REFERENCES

- Jeremías Torruella X, 2002. Miasis cutáneas. *Piel* 17: 300–309.
- Soler Cruz M, 2000. The study of myiasis in Spain during the past century. *Ars Pharm* 41: 19–26.
- Espinoza A, Quiñones-Silva J, Garay O, 2009. Myiasis in oral cavity by *Cochliomyia hominivorax*: a case report. *Rev Peru Med Exp Salud Publica* 26: 573–576.
- Alcalá D, Yáñez S, 2006. Miasis furuncular causada por *Dermatobia hominis*. *Rev Cent Dermatol Pascua* 15: 23–25.
- Batista-da-Silva JA, Borja GEM, Queiroz MMC, 2011. Patient with tracheostomy parasitized in hospital by larvae of the screw-worm, *Cochliomyia hominivorax*. *J Insect Sci* 11: 163.
- Olea MS et al., 2014. First report of myiasis caused by *Cochliomyia hominivorax* (Diptera: Calliphoridae) in a diabetic foot ulcer patient in Argentina. *Korean J Parasitol* 52: 89–92.
- Francesconi F, Lupi O, 2012. Myiasis. *Clin Microbiol Rev* 25: 79–105.
- Mathison BA, Pritt BS, 2014. Laboratory identification of *Arthropod* ectoparasites. *Clin Microbiol Rev* 27: 48.
- Beltrán M, Torres G, Segami H, Náquira C, 2006. Miasis ocular por *Oestrus ovis*. *Rev Peru Med Exp Salud Publica* 23: 48–67.
- Miranda H, 2007. Miasis en Trujillo, Perú: observaciones clínicas y entomológicas. *Folia Dermatol.* 18: 13–17.
- Failoc-Rojas VE, Silva-Díaz H, 2016. Review of cases and a patient report of myiasis with tracheostomy, Peru. *Emerg Infect Dis* 22: 563–565.
- Sánchez-Sánchez R, Calderón-Arguedas O, Mora-Brenes N, Troyo A, 2014. Miasis nosocomiales en América Latina y el Caribe: ¿una realidad ignorada? *Rev Panam Salud Publica* 36: 201–205.
- Rossi MA, Zucoloto S, 1973. Fatal cerebral myiasis caused by the tropical warble fly, *Dermatobia hominis*. *Am J Trop Med Hyg* 22: 267–269.
- Ferrero-Becerra EG, 2011. Miasis en salud pública y salud pública veterinaria. *Revista Sapuvel de Salud Pública* 2: 95–132.
- Lau S, Langstaff I, Ryan NJ, 2015. Imported New World screw-worm fly myiasis. *Med J Aust* 203: 435.