

## Original Article

# Primary unilateral cleft lip nasal deformity repair using V-Y-Z plasty: An anthropometric study

Percy Rossell-Perry<sup>1,2</sup>

<sup>1</sup>Post Graduate Studies Department Faculty of Medicine, San Martin de Porres University, Lima, Peru, <sup>2</sup>Outreach Surgical Center, Lima Perú ReSurge International, Sunnyvale, CA 94086, USA

**Address for correspondence:** Dr. Percy Rossell-Perry, Schell Street Number 120 Apartment 1503 Miraflores, Lima 18, Peru.  
E-mail: prossellperry@gmail.com

### ABSTRACT

**Background:** Secondary nose deformity after unilateral cleft lip repair is a common problem. Loss of tip projection on the cleft side of unilateral cleft lip nasal deformity can be difficult to correct due to lack of adequate support. The purpose of this study is to evaluate the surgical outcome after using V-Y-Z plasty to address unilateral cleft lip nasal deformities. **Methods:** A cross-sectional study of one surgeon's outcome of 58 performed primary complete unilateral cleft lip nasal deformity repairs. All these patients met the study criterion of having anthropometric measurements at the cleft and non-cleft side of the nose performed at least 1 year postoperatively. **Results:** Since 2012, 32 consecutive patients have undergone primary anatomical repair of the cleft nasal deformity in patients with a complete unilateral cleft. We have not found statistically significant differences between the cleft and non-cleft nostril dome height and columella length measured at least 1 year postoperatively. **Conclusions:** The findings suggest that the V-Y-Z plasty is a good alternative to create a more symmetric nasal tip in patients with primary unilateral cleft lip nasal deformity. Additional studies are required to evaluate functional and long-term outcomes after primary rhinoplasty in patients with unilateral cleft lip.

### KEY WORDS

Cleft rhinoplasty; nose deformity; unilateral cleft lip

### INTRODUCTION


Secondary nose deformity after unilateral cleft lip repair is a common problem. Loss of nose tip projection on the affected side can be difficult to correct due to lack of proper structural support. The nasal deformity associated with unilateral cleft lip and palate

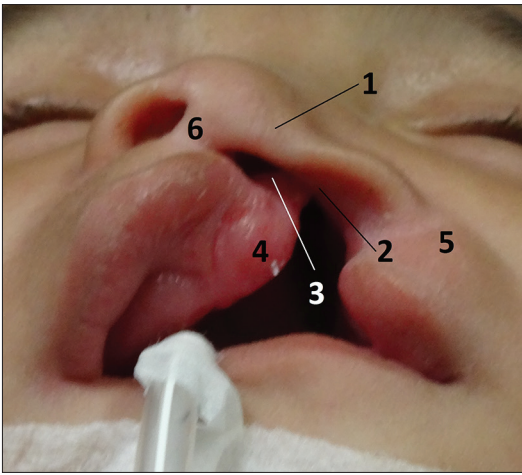
involves skeletal and soft tissue structures [Figure 1]. Although many studies<sup>[1-4]</sup> have reported the use of primary rhinoplasty at the time of cleft lip repair, secondary correction of residual unilateral cleft lip nasal deformities is often necessary for functional and cosmetic purposes. This is primarily due to incomplete correction of the primary nose deformity, which leaves the skeleton

This is an open access article distributed under the terms of the Creative Commons Attribution-NonCommercial-ShareAlike 3.0 License, which allows others to remix, tweak, and build upon the work non-commercially, as long as the author is credited and the new creations are licensed under the identical terms.

**For reprints contact:** reprints@medknow.com

**How to cite this article:** Rossell-Perry P. Primary unilateral cleft lip nasal deformity repair using V-Y-Z plasty: An anthropometric study. *Indian J Plast Surg* 2017;50:180-6.

Access this article online	
Quick Response Code:	Website: www.ijps.org
	DOI: 10.4103/ijps.IJPS_215_16



**Figure 1:** The complete unilateral cleft lip nose and palate deformity and its basic components: (1) Alar cartilage malposition. (2) Shortened vestibule of the nose. (3) Septal deviation. (4) Skeletal deformity (maxillary cleft). (5) Muscular abnormal insertion (6) Retracted appearance of the columella

and nasal septum unrepaired. Many authors<sup>[5-7]</sup> have reported studies on this topic; however, few studies have addressed all nasal components and objectively evaluated patient outcomes.

Our surgical protocol addresses all five components of cleft lip deformity: alar cartilage malposition, shortened nose vestibule, muscular abnormal insertion, skeletal deformity (septal deviation and maxillary cleft) and foreshortened columella with retracted appearance [Figure 1]. The main defect is the position of the ala. The alar cartilage lies caudal and lateral to the contralateral side and is tethered by an abnormal attachment to the pyriform aperture. This structure rests on an underdeveloped maxilla, which accounts for alar base lowering. The nasal vestibule after primary repair is frequently smaller, which indicates that this area should be lengthened during the primary procedure. The tip of the nose is a combination of two factors, including incomplete projection and a deviated columella that lies obliquely with its base oriented away from the cleft side [Figure 1]. The septum may be displaced away from the cleft to different degrees, and dorsal septal curvature is present [Figure 1]. In addition, their muscular pull is imbalanced, and the cheek muscles are abnormally attached to the lateral crus. The skeleton is frequently affected, with an observable widening at the dorsum and the frontal process of the maxilla.

The V-Y composite flap technique was first described by Potter in 1954,<sup>[8]</sup> and it is frequently used for secondary cleft rhinoplasty.<sup>[2,9,10]</sup> However, the V-Y method leaves a straight scar in the lateral segment of the closure, which

may create a lateral scar contracture of the vestibule. The utility of this method in primary unilateral cleft lip nose repair is not well described in the literature. A variation of this technique with extended mucosal tab was published by Cronin *et al.* in 2004<sup>[2]</sup> with good results. This method uses mucosa for vestibular skin repair. A comprehensive care protocol for correction of cleft nasal deformities using the Cronin surgical technique and post-operative outcomes is presented here. The purpose of this study was to evaluate nose symmetry after using these protocols for primary complete unilateral cleft lip nasal deformities.

## METHODS

### Patients and study design

This is a cross-sectional study of one surgeon's outcome following 32 consecutive complete unilateral cleft lip nasal deformity repairs. All patients had a primary cheilorhinoplasty including the following four procedures: (i) cheiloplasty using surgical techniques based on the author's protocol;<sup>[11,12]</sup> (ii) medial mobilisation of the affected lateral alar crus and vestibular lengthening using the V-Y-Z technique [Figures 2 and 3]; (iii) caudal septoplasty and (iv) labionasal muscular repair.

Follow-up was performed at least 1 year after the surgical procedure. During follow-up, all patients were subjected to the following three anthropometric measurements [Figure 4]: (i) nostril dome height, which was measured from the lateral border at the base of the columella to the highest point on the nasal dome on each side; (ii) columella length, which was measured from the lateral border at the base of the columella to the highest point of the nostril and (iii) alar width, which was measured from the lateral border at the base of the columella to the most lateral point of the ala in a line perpendicular to the axis of the columella. All three measurements were performed on both the cleft and non-cleft sides of the nose.

### Surgical technique

We did not perform any type of pre-surgical management for any of the patients. The surgical repair of the nose was conducted during primary cheiloplasty. The nose was dissected before lip repair, which enables good access to the structures and facilitates more accurate repair of all components. Alar cartilage dissection and vestibular nose lengthening were performed using the V-Y-Z method. Therefore, the skin incision along the marginal

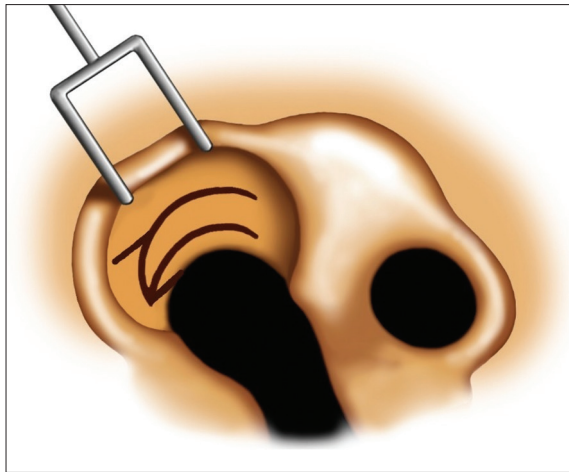

Figure 2: The V-Y-Z technique for complete unilateral cleft lip nose repair

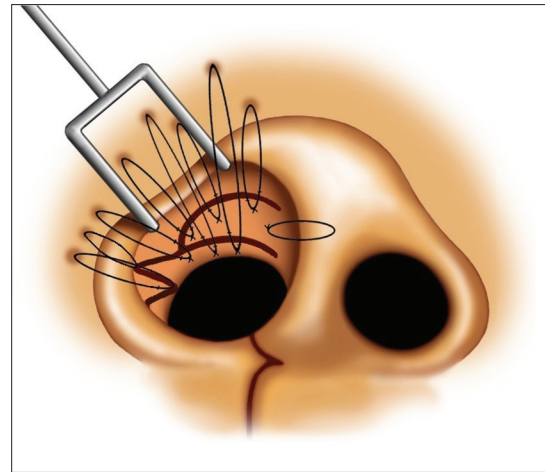


Figure 3: The V-Y-Z closure using transcutaneous stitches with medial V-Y plasty and lateral Z-plasty components

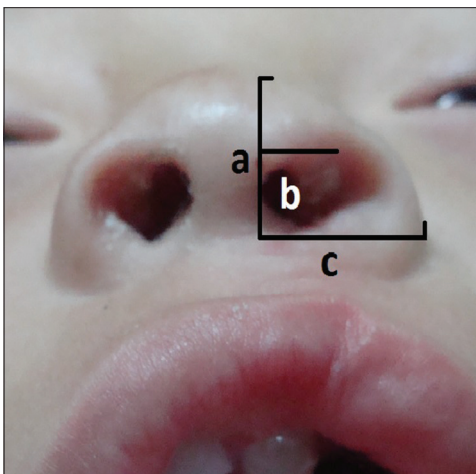


Figure 4: Standard anthropometric measurements. (a) Nostril dome height, (b) Columella length and (c) Alar width

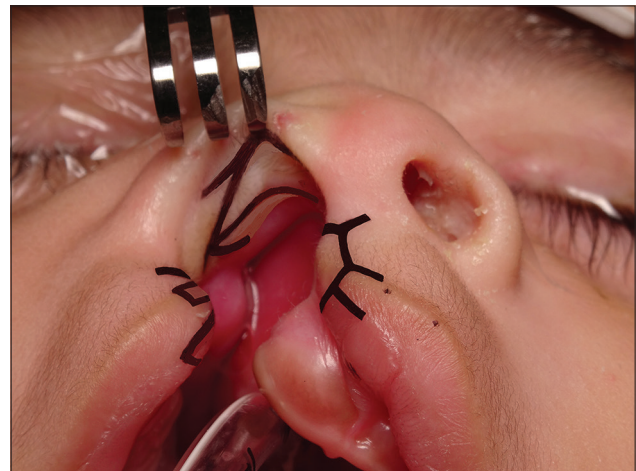
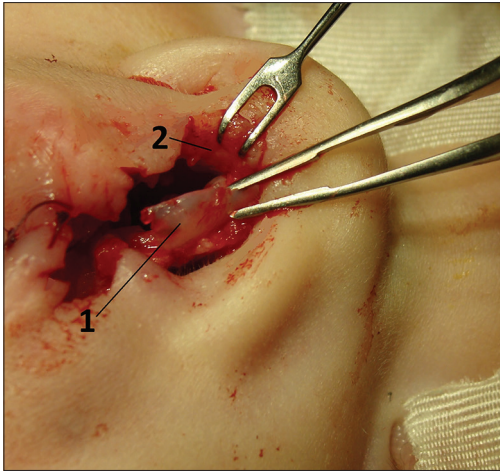


Figure 5: Pre-operative design of the V-Y-Z technique

and intercartilaginous borders was performed to create a composite flap (vestibular skin and alar cartilage) in a V form, and the two limbs of the lateral Z-plasty were incised and elevated [Figure 5]. The bilateral cartilage structures of the nose tip were dissected using this incision. Alar cartilages were then degloved at the nasal tip level. Subsequently, the flap was displaced medially, and the lateral flaps were transposed in a Z-plasty form. All incisions were closed using transcutaneous sutures [Figures 2 and 3]. A transcutaneous interdomal suture was placed first, then the lateral genu of the alar cartilage was elevated using vertical transcutaneous sutures as illustrated in Figure 3. We used 5-0 polyglycolic acid sutures through the skin starting inside the nose, then coming out at the level of the supra-alar crease, returning through the same hole and finally coming out inside the nose and tying the sutures [Figure 3]. The use of these sutures in combination with the V-Y-Z method allowed us to obtain the following three objectives: (i) reposition

the alar cartilage and lengthen the columella at the cleft side; (ii) lengthen the nasal vestibule and prevention of scar contracture using a lateral Z-plasty and (iii) reduce the space created by surgical dissection, which reduces the risk of post-operative bleeding and haematoma formation.

We did not use cartilage grafts for primary cleft rhinoplasty. A retrocolumellar incision enabled access to the most anterior portion of the septum. The caudal septum correction was performed through this incision. The mucoperichondrium was elevated from the septum on both sides. The septal cartilage was released from its abnormal attachment and fixed to the opposite side [Figure 6]. Finally, the incision was closed using transcutaneous 5-0 polyglycolic acid sutures. The nasal floor was repaired by properly locating the ala, thereby shortening the nasal base width. During cheiloplasty, the levator labii superioris alaeque nasi and orbicularis



**Figure 6:** Caudal septoplasty during primary cheilorhinoplasty in a patient with complete unilateral cleft lip and palate. (1) Caudal septum. (2) Mucoperichondrium flap

oris muscles were identified and repositioned. The labial muscle reconstruction helps us to bring support to the nasal floor. Nasal packing was used in all cases inside the operated nostril to prevent post-operative bleeding; this packing should be removed 1 day after surgery. Post-operative nostril stenting was not used.

**Statistical analysis**

Matched pair *t*-test analyses were performed when the required assumptions were met. When the normality assumption was not met, the non-parametric Wilcoxon signed-rank test was used to assess the statistical significance of differences between the cleft and non-cleft sides. A value of *P* < 0.05 yielded 95% confidence interval. All statistical analyses were conducted using SPSS version 15.0 (SPSS Inc., Chicago, IL, USA).

**RESULTS**

Thirty-two consecutive patients with complete unilateral cleft lip nose deformity repair received the proposed surgical technique and follow-up measurements since 2012. The mean age at the time of the surgery was 5.8 months (range, 3–7 months). The mean time of follow-up evaluation was 1.9 years (range, 1.2–2.7 years). The patient characteristics are summarised in Table 1: there were 18 male (56.25%) and 14 female (43.75%) patients; the male-to-female ratio was 1.23 and 21 patients were affected on the left side (65.62%), whereas 11 patients were affected on the right side (34.37%). We observed slight differences in post-operative nostril dome height and columella length between the cleft and non-cleft sides, but these differences were not statistically

**Table 1: Operative characteristics**

Characteristic	Value
Operative time (minutes)	47.5±15.2
History of cleft lip repair*	
Modified Nakajima	18 (56.25%)
Triple Unilimb Z Plasty	14 (43.75%)

\*Selection based on Outreach Surgical Center Lima protocol

significant (*P* = 0.49 and 0.48, respectively) [Table 2]. We did observe a statistically significant difference in alar width on the cleft side versus the non-cleft side (*P* = 0.0001) [Table 2]. Nose asymmetry with respect to at least one of the measured parameters was observed in seven of the operated cases (21.88%). These cases required minor revisions. None of the studied cases required major revisions. Surgical outcomes are presented in Figures 7-10.

**DISCUSSION**

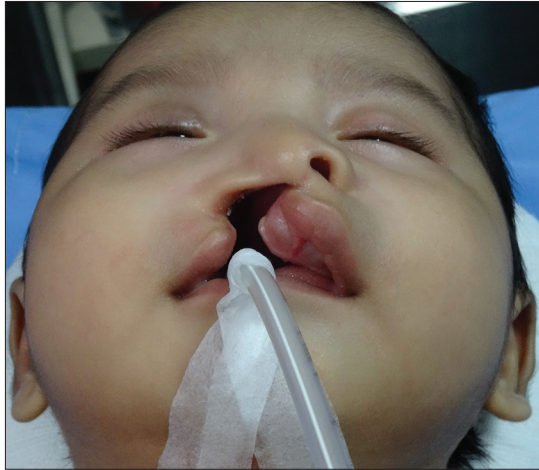Rhinoplasty in patients with unilateral cleft lip nose deformity poses a technical challenge for plastic surgeons. The main problems are achieving caudal nose congruity and creating symmetric nostrils. The main objectives for correcting unilateral cleft lip nose deformities are reorientation of the abnormal nasal anatomy and creation of a balanced platform. Although many studies have addressed this problem,<sup>[1-7]</sup> most of them include pre-surgical nasal moulding and limited correction of the nose deformity but do not include vestibular and septal repair. The anatomy of the unilateral cleft lip nose deformity exhibits different components and degrees of severity, which requires careful pre-operative evaluation.

The present study proposes a surgical technique and protocol that considers the correction of each basic component involved in unilateral cleft lip nose deformity, with the exception of the skeleton, which is repaired at a later age. The efficacy of the proposed technique for primary cleft nose deformity repair was confirmed by the post-operative measurements and insignificant differences in nostril dome height and columella length between the cleft and non-cleft side [Table 2 and Figures 7-10]. Previous studies (Cutting 2003)<sup>[11-13]</sup> reported differences in alar width between the cleft and non-cleft sides. This unfavourable result may be related to the development of hypertrophic scar due to tension of the closure or facial muscle activity. This unfavourable outcome can be easily corrected by conducting a minor revision.

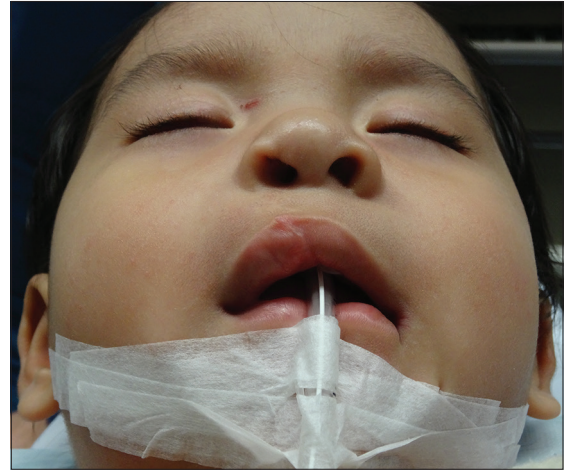**Table 2: Postoperative comparisons of Non-Cleft side and Cleft side using the V-Y-Z plasty**

Nose segment	Non-cleft side (n=32) mean (SD)	Cleft side (n=32) mean (SD)	P	CL
Nostril dome height*	9.875 (1.039541)	9.625 (0.975506)	0.0831	0.913842-0.408615
Columella Length*	5.156 (0.846601)	4.937 (0.800705)	0.1606	0.673190-0.370181
Alar width**	13.125 (0.870669)	14.251 (0.803219)	0.00001	-1.425255-0.824745

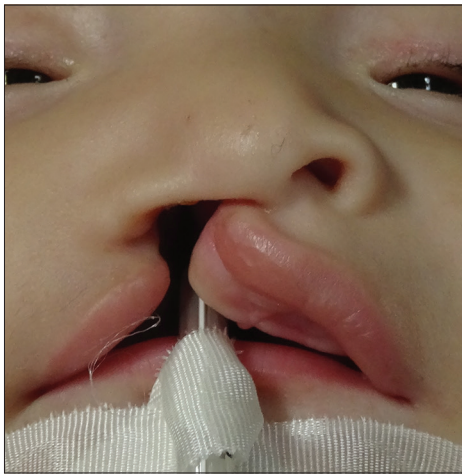\* Paired student t-test. \*\*Wilcoxon signed rank test



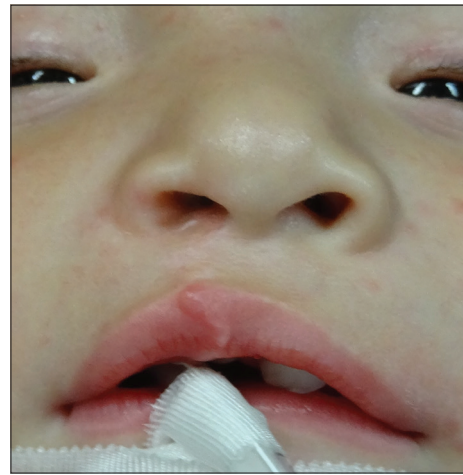**Figure 7:** Case 1. A 3-month-old male patient with a right complete unilateral cleft lip nose and palate deformity



**Figure 8:** Post-operative view of the patient after surgery illustrating cosmetic improvement of the nose after 1 year



**Figure 9:** Case 2. A 3-month-old female patient with a right complete unilateral cleft lip nose and palate deformity



**Figure 10:** Post-operative view of the patient after surgery illustrating cosmetic improvement of the nose after 1 year

Our results indicate that only 21.88% of the studied cases required minor surgical revision, and none of the cases required a reoperation. Therefore, patient outcomes after our surgical protocol are better than those after other procedures such as the outcomes reported by Cohen with 76.4% improvement,<sup>[14]</sup> and 55.80% of reoperation cases observed by Haddock.<sup>[1]</sup> Considering these combined results, we propose three main conclusions: (a) the columella does not require lengthening using the 'c' flap as proposed by Millard.<sup>[15]</sup> The columella can be effectively repaired by alar repositioning and vestibular lengthening. Reshaping the nasal ala is sufficient to restore columella

length. (b) Several studies in primary and secondary cleft nose rhinoplasty indicate that vestibular lengthening is necessary to obtain nose symmetry.<sup>[1-7]</sup> The nose tissues should be preserved and not resected as recently proposed by Patel and Mulliken.<sup>[16]</sup> (c) The necessity of pre-surgical management lacks scientific support and should be considered as an alternative strategy.

Different studies (including systematic reviews) describe the absence of scientific evidence supporting the use of pre-surgical management for unilateral cleft nose repair.<sup>[17-19]</sup> Significant relapse of the deformity has been

observed after using nasal mouldings,<sup>[20,21]</sup> and better outcomes were observed only in combination with primary rhinoplasty.<sup>[22]</sup> Good nose symmetry can be obtained as demonstrated in the current study using an adequate surgical technique without pre-surgical treatment. Cleft segments do not require pre-operative plate guidance; the orbicularis oris muscle is moving the segments to proper position in a physiological form bringing support for the repaired nose. Cartilage tip grafts are commonly used in cleft nose deformity repair; however, we did not use them because tip projection can be achieved with the proper mobilisation of the affected alar cartilage [as shown in Figures 7-10]. A recent study of Yoshimura *et al.*<sup>[23]</sup> suggests that performing nasal repair at the time of primary cleft lip surgery adversely affects nose growth. By contrast, many studies have reported normal nose growth after primary rhinoplasty.<sup>[24,25]</sup> Yoshimura *et al.*<sup>[23]</sup> performed an observational study with a small sample size. This issue remains controversial and requires better scientific evidence in future. Here, we did not evaluate functional and long-term outcomes, and additional studies to address patient outcomes will be required.

## CONCLUSIONS

This study demonstrates the efficacy of the proposed surgical technique for obtaining nose symmetry in patients with unilateral cleft lip nasal deformity. These results suggest that the proposed protocol is a good alternative to address primary nose deformity related to unilateral cleft lip, and the protocol may reduce secondary procedures. Additional studies are required to evaluate functional and long-term outcomes after primary rhinoplasty in patients with unilateral cleft lip nose deformity.

### Declaration of patient consent

The authors certify that they have obtained all appropriate patient consent forms. In the form the patient(s) has/have given his/her/their consent for his/her/their images and other clinical information to be reported in the journal. The patients understand that their names and initials will not be published and due efforts will be made to conceal their identity, but anonymity cannot be guaranteed.

### Financial support and sponsorship

Nil.

### Conflicts of interest

There are no conflicts of interest.

## REFERENCES

1. Talmant JC, Talmant JC, Lumineau JP. Primary treatment of cleft lip and palate. Its fundamental principles. *Ann Chir Plast Esthet* 2016;61:348-59.
2. Cronin ED, Rafols FJ, Shayani P, Al-Haj I. Primary cleft nasal repair: The composite V-Y flap with extended mucosal tab. *Ann Plast Surg* 2004;53:102-8.
3. LaRossa D, Donath G. Primary nasoplasty in unilateral and bilateral cleft nasal deformity. *Clin Plast Surg* 1993;20:781-91.
4. Narayanan P, Adenwalla H. Primary rhinoplasty at the time of unilateral cleft lip repair: A review and our protocol. *J Cleft Lip Palate Craniofacial Anomalies* 2015;2:92-7.
5. Salyer KE, Genecov ER, Genecov DG. Unilateral cleft lip-nose repair: A 33-year experience. *J Craniofac Surg* 2003;14:549-58.
6. Wolfe SA, Nathan NR, MacArthur IR. The cleft lip nose: Primary and secondary treatment. *Clin Plast Surg* 2016;43:213-21.
7. Thomas C, Mishra P. Open tip rhinoplasty along with the repair of cleft lip in cleft lip and palate cases. *Br J Plast Surg* 2000;53:1-6.
8. Potter J. Some nasal tip deformities due to alar cartilage abnormalities. *Plast Reconstr Surg* 1954;13:358-66.
9. Talmant JC, Talmant JC. Cleft rhinoplasty, from primary to secondary surgery. *Ann Chir Plast Esthet* 2014;59:555-84.
10. Basta MN, Goldstein JA, Wilson AJ, Taylor JA. A modified V-Y chondromucosal composite flap for correction of secondary cleft nasal deformity: Photogrammetric analysis of a case-control study. *Plast Reconstr Surg* 2014;134:94-101.
11. Rossell-Perry P, Gavino-Gutierrez AM. Upper double-rotation advancement method for unilateral cleft lip repair of severe forms: Classification and surgical technique. *J Craniofac Surg* 2011;22:2036-42.
12. Rossell-Perry P. A 20-year experience in unilateral cleft lip repair: From Millard to the triple unilimb Z-plasty technique. *Indian J Plast Surg* 2016;49:340-9.
13. Cutting CB, Dayan JH. Lip height and lip width after extended Mohler unilateral cleft lip repair. *Plast Reconstr Surg* 2003;111:17-23.
14. Cohen M, Morris DE, White AD, Patel P. Functional and aesthetic correction of secondary unilateral cleft lip nasal deformities. *Indian J Plast Surg* 2009;42 Suppl S1:91-101.
15. Millard R Jr. A primary camouflage of the unilateral hare-lip. In: *Transactions of the International Society of Plastic Surgeons*. Baltimore: Williams and Wilkins; 1957. p. 60.
16. Patel KB, Mulliken JB. Correction of the vestibular web during primary repair of unilateral cleft lip. *Plast Reconstr Surg* 2014;134:600e-7e.
17. van der Heijden P, Dijkstra PU, Stellingsma C, van der Laan BF, Korsten-Meijer AG, Goorhuis-Brouwer SM. Limited evidence for the effect of presurgical nasoalveolar molding in unilateral cleft on nasal symmetry: A call for unified research. *Plast Reconstr Surg* 2013;131:62e-71e.
18. Levy-Bercowski D, Abreu A, DeLeon E, Looney S, Stockstill J, Weiler M, *et al.* Complications and solutions in presurgical nasoalveolar molding therapy. *Cleft Palate Craniofac J* 2009;46:521-8.
19. Uzel A, Alparslan ZN. Long-term effects of presurgical infant orthopedics in patients with cleft lip and palate: A systematic review. *Cleft Palate Craniofac J* 2011;48:587-95.
20. Pai BC, Ko EW, Huang CS, Liou EJ. Symmetry of the nose after presurgical nasoalveolar molding in infants with unilateral cleft lip and palate: A preliminary study. *Cleft Palate Craniofac J* 2005;42:658-63.
21. Liou EJ, Subramanian M, Chen PK, Huang CS. The progressive

- changes of nasal symmetry and growth after nasoalveolar molding: A three-year follow-up study. *Plast Reconstr Surg* 2004;114:858-64.
22. Chang CS, Por YC, Liou EJ, Chang CJ, Chen PK, Noordhoff MS. Long-term comparison of four techniques for obtaining nasal symmetry in unilateral complete cleft lip patients: A single surgeon's experience. *Plast Reconstr Surg* 2010;126:1276-84.
  23. Yoshimura Y, Okumoto T, Iijima Y, Inoue Y. Reduced nasal growth after primary nasal repair combined with cleft lip surgery. *J Plast Reconstr Aesthet Surg* 2015;68:e159-66.
  24. Farouk A. Rhinoplasty in clefts: An 18-year retrospective review. *Facial Plast Surg* 2015;31:539-52.
  25. Kaufman Y, Buchanan EP, Wolfswinkel EM, Weathers WM, Stal S. Cleft nasal deformity and rhinoplasty. *Semin Plast Surg* 2012;26:184-90.