



CASE REPORT

REVISED Case Report: Double penile fracture [version 2; peer review: 2 approved]

Felipe Mercado-Olivares¹, J. Antonio Grandez-Urbina²⁻⁴, Giomar Farfan-Daza⁵, Juan Pacheco-Sauñe⁵, Luciano Nuñez-Bragayrac²

- ¹Department of Medicine, Universidad San Martin de Porres, Lima, Peru
- ²Department of Urology, Clinica de Urologia Avanzada UROZEN, Lima, 15021, Peru
- ³Biomedical Research Institute, Universidad Ricardo Palma, Lima, Peru
- ⁴Universidad Continental, Lima, Peru
- ⁵Department of Urology, Hospital Nacional ESSALUD Alberto Sabogal Sologuren, Callao, Peru

v2 First published: 21 Nov 2018, 7:1828
<https://doi.org/10.12688/f1000research.16452.1>
 Latest published: 21 Aug 2019, 7:1828
<https://doi.org/10.12688/f1000research.16452.2>

Abstract

Penile fracture is an underreported surgical emergency. It usually occurs as a single rupture of the tunica albuginea in one of two corpora cavernosa; a rupture of both masses is an uncommon finding. We report a case of a young male who presented to the emergency department two hours after sustaining penile trauma. Prompt surgical exploration was performed four hours post-injury. He was found to have one fracture on each corpora cavernosa, without urethral injury, which were repaired successfully. The patient had a favorable recovery and was discharged on the third postoperative day without complications. The aim of this report is to highlight the importance of complete degloving of the penile shaft for a meticulous search during surgery to avoid missed injuries. This approach will ensure a successful outcome avoiding physical and psychological disabilities.

Keywords

Penile Diseases, Urologic Surgical Procedures, Injuries, Penile induration

Open Peer Review

Reviewer Status

| | Invited Reviewers | |
|-----------------------------------------------|-------------------|----------------|
| | 1 | 2 |
| version 2 (revision) 21 Aug 2019 | | report |
| version 1 21 Nov 2018 | report | report |

- 1 **Rodrigo Barros** , Hospital Municipal Souza Aguiar, Rio de Janeiro, Brazil
- 2 **Sameer Trivedi** , Institute of Medical Sciences, Banarus, India

Any reports and responses or comments on the article can be found at the end of the article.

Corresponding author: J. Antonio Grandez-Urbina (jgrandez@continental.edu.pe)

Author roles: **Mercado-Olivares F:** Conceptualization, Writing – Original Draft Preparation, Writing – Review & Editing; **Grandez-Urbina JA:** Conceptualization, Writing – Original Draft Preparation, Writing – Review & Editing; **Farfan-Daza G:** Supervision, Writing – Review & Editing; **Pacheco-Saña J:** Supervision, Writing – Review & Editing; **Nuñez-Bragayrac L:** Supervision, Writing – Review & Editing

Competing interests: No competing interests were disclosed.

Grant information: The author(s) declared that no grants were involved in supporting this work.

Copyright: © 2019 Mercado-Olivares F *et al.* This is an open access article distributed under the terms of the [Creative Commons Attribution License](#), which permits unrestricted use, distribution, and reproduction in any medium, provided the original work is properly cited.

How to cite this article: Mercado-Olivares F, Grandez-Urbina JA, Farfan-Daza G *et al.* **Case Report: Double penile fracture [version 2; peer review: 2 approved]** F1000Research 2019, 7:1828 <https://doi.org/10.12688/f1000research.16452.2>

First published: 21 Nov 2018, 7:1828 <https://doi.org/10.12688/f1000research.16452.1>

REVISED Amendments from Version 1

"Universidad Continental, Lima, Peru" has been added as an affiliation for J. Antonio Grandez-Urbina in this version.

We realize and mention that there are other etiologies related to penile fracture such as, "Taqandand", which is practiced in Middle Eastern countries. We have edited the discussion adding the percentage and absolute number of patients that present double penile fracture in a case series. Also, we mentioned the role of imaging in the study of penile fracture and added techniques used to detect urethral injuries.

We recognized that more research is needed on this topic to make firm recommendations.

See referee reports

Introduction

Fracture of the penis, or *faux pas du coit*, is an uncommon surgical emergency that occurs as a result of trauma to the erect penis^{1,2}. The incidence of penile injuries is underreported because many patients do not seek medical attention³. Penile fracture is defined as the rupture of the tunica albuginea and the corpora cavernosa⁴. Most cases occur during sexual intercourse, usually due to hitting the symphysis pubis or the perineum after the penis slips out of the vagina; less commonly reported is during masturbation^{2,3}.

It is manifested by a cracking or popping sound accompanied by immediate detumescence, followed by rapid swelling, widespread ecchymosis, sharp pain and deformity (away from the trauma site)^{2,5}.

This condition can be quickly diagnosed after history taking, physical examination and imaging. Prompt diagnosis and early surgical repair are essential to ensure a successful outcome^{6,7}.

It is uncommon for a penile fracture to involve both of the corpora cavernosa. We report a rare case of a double penile fracture and describe its presentation and management.

Case report

A 32-year-old patient presented to the emergency department two hours after having penile trauma during vigorous sexual intercourse. He was having sexual intercourse in a 'woman-on-top' position when he heard a 'snap' sound followed by severe pain and immediate loss of tumescence. On physical examination, his penis was swollen, deformed, and with signs of ecchymosis. On admission, two ventral irregularities were found during penile palpation (Figure 1). There was no urethral bleeding, nor voiding difficulties suggesting an uncompromised urethra. During the patient's consultation, no previous sexual disorders were found and the patient denied the usage of PDE5 inhibitors or intra-cavernosum injections. Labs results were within normal limits and radiological images were not obtained prior to surgical intervention due to lack of resources.

Cefazoline 2gr IV was administered prophylactically before surgery. Emergency exploration was performed 4 hours post-penile injury. A 16 Fr. Foley catheter was placed without

difficulties. Then a circumcision was made, and surgical exploration was performed. On degloving the penile skin, a fracture on each corpora cavernosa was found. The length of the right and left defects were 25mm and 35mm, respectively (Figure 2).



Figure 1. Swollen and deformed fractured penis.

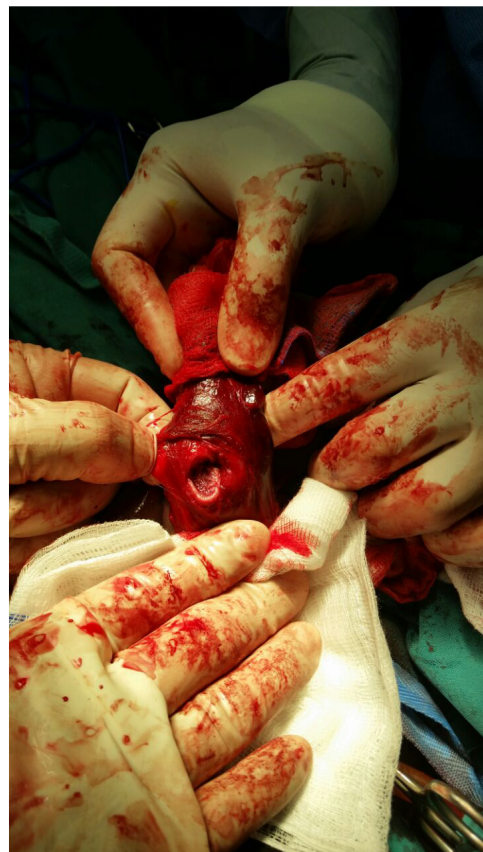


Figure 2. Exposure of one of the fractured corpora cavernosa after penile degloving during surgical treatment.

In order to protect the urethra, a Penrose drain was used as a vessel loop through the double fracture separating it from the site of injury (Figure 3). Repair of the two lacerations was done using 3-0 Vicryl in a continuous suture pattern. The Foley catheter was removed the next day without adverse events. The patient had a favorable recovery and was discharged three days after the surgical procedure without any complication (Figure 4).

At a follow-up period of 90 days, the patient had a proper erectile function, no deformity, no pain during sexual intercourse, and no voiding difficulties.

Discussion

The penis is composed of erectile tissue arranged in a columnar fashion. Two dorsolateral corpora cavernosa and one ventral corpus spongiosum, each enclosed by the tunica albuginea. The urethra traverse the corpus spongiosum throughout its length. The distal expansion of the corpus spongiosum forms the glans penis. Buck's fascia encloses the corpus spongiosum ventrally, and splits dorsally to surround the two corpora cavernosa^{1,4,5}.

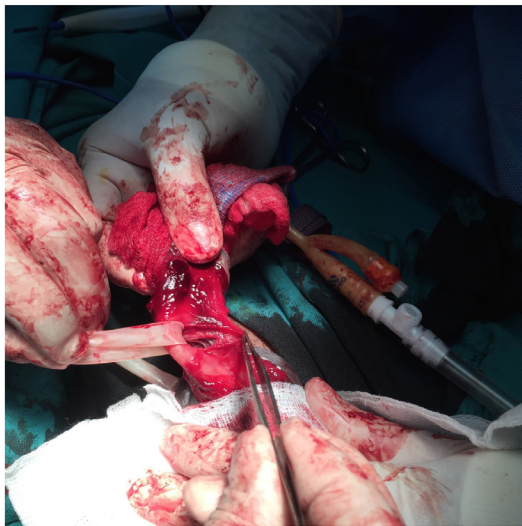

Figure 3. Protection of the urethra during surgery using a Penrose drain through the double fracture.



Figure 4. Second post-op day after repair of double penile fracture.

Penile fracture, or *faux pas du coit*, is an underreported but emergent urological condition⁸. It's underreported because many patients do not seek medical attention due to embarrassment, shame, or lack of guidance³. Activities that can result in penile fracture includes self-manipulation to achieve tumescence, sexual intercourse, turning over in bed, a direct blow to the erect penis and interrupting the erection due to a violent bending of their penis called "Taqaandan"^{2,4,9}. The most common cause is sexual intercourse, with injuries often caused by different sexual positions. In an original article published in 2017, Barros *et al.* reported that 'doggy style' was more commonly associated with double fractures out of 67 patients (10%) presented double corpus cavernosum lesión¹⁰. In fact, any activity associated with tumescence can increase the chance of penile fractures. In 2002, Blake *et al.* reported the first case of a fracture related to pharmacologically induced erections¹¹. The increased risk of penile fractures during tumescence is related to the tunica albuginea stretching and thinning. The thickness of the tunica reduces from 2.4mm, in the flaccid state, to 0.25-0.5mm in the erect form¹².

The most extensive review of cases was made by Eke between 1935 and 2001. He analyzed 1331 cases from 183 publications. Most reports were from the Mediterranean region; the median age of patients were 35 years. Clinical features included sudden penile pain, detumescence, voiding difficulties, penile swelling and deviation. Associated injuries included urethral rupture. Complications of the rupture included coital difficulty, urethral fistula, penile plaque and erectile dysfunction¹.

The diagnosis is mainly clinical, although in the absence of typical signs it can pose a real challenge. Therefore, an adequate history and physical examination are cornerstones of the diagnostic process. In our patient, radiologic investigations were not performed due to lack of resources and the diagnosis was based solely on physical examination findings. Most cases reported in literature describes imaging modalities being used to exclude the presence of a concomitant urethral injury and to delineate the exact location of the albuginea rupture¹³. Various imaging modalities have been used to aid in the diagnosis, such as cavernosography, retrograde urethrography, ultrasonography-colour Doppler, and magnetic resonance. Cavernosography is an invasive method that is rarely used. Retrograde urethrography is also an invasive method, but is required only if associated urethral injury is suspected⁷. Ultrasonography is the modality most frequently used because of its cost and availability. Magnetic resonance imagine is the most accurate method to localize the lesions, but its availability is limited due to its cost¹⁴. We would prefer to use MRI in this case in order to support the surgical decision, but the role of imaging is largely limited to unclear cases with equivocal findings or unreliable history¹⁵.

Most studies report a solitary fracture of the corpora cavernosa. In our patient, both corpus were found to have fractures. Although no imaging modalities were performed, the omission of careful surgical exploration for the second site of injury might have led to unsatisfactory outcomes. Therefore, it seems essential to make a complete surgical exploration, degloving the penile shaft, while operating upon such cases.

Urgent surgery is the recognized gold standard approach. However, recent studies have revealed that long-term outcomes of early versus delayed repair in patients without urethral involvement are similar^{16,17}. In 2011, Kozacioglu et al. evaluated 56 patients who underwent early and delayed penile fracture repair. Their study noted no serious deformities nor erectile dysfunction in the long term as a result of a delay in surgery in patients without urethral involvement⁵. It would be useful to use intra-operative manoeuvres like urethral injection of methylene blue in order to detect occult urethral injuries. In our case, surgical repair was offered early in the course of the presentation. The outcome was favorable and no complications were noted on follow-up.

Conclusion

Double rupture of the tunic albuginea is a rare finding in penile fractures. The diagnosis is clinical; however imaging should be used to help delineate the exact location and extent of injury. Degloving of the entire penis is recommended to identify possible

multiple fractures, urethral damage, and damage to nearby structures. In our case, surgical repair was performed early which led to a successful recovery without complications. This case report is intended to further increase the literature helping physicians in search of experiences managing this low incidence condition.

Consent

Written informed consent for publication of their clinical details and/or clinical images was obtained from the patient.

Data availability

All data underlying the results are available as part of the article and no additional source data are required.

Grant information

The author(s) declared that no grant(s) were involved in supporting this work.

References

- Eke N: **Fracture of the penis.** *Br J Surg.* 2002; **89**(5): 555–65. [PubMed Abstract](#)
- Fergany AF, Angermeier KW, Montague DK: **Review of Cleveland Clinic experience with penile fracture.** *Urology.* 1999; **54**(2): 352–5. [PubMed Abstract](#) | [Publisher Full Text](#)
- Krishna Reddy SV, Shaik AB, Sreenivas K: **Penile injuries: A 10-year experience.** *Can Urol Assoc J.* 2014; **8**(9–10): E626–31. [PubMed Abstract](#) | [Publisher Full Text](#) | [Free Full Text](#)
- Kachewar S, Kulkarni D: **Ultrasound evaluation of penile fractures.** *Biomed Imaging Interv J.* 2011; **7**(4): e27. [citado 9 de octubre de 2018]. [PubMed Abstract](#) | [Free Full Text](#)
- Kozacioglu Z, Degirmenci T, Arslan M, et al.: **Long-term significance of the number of hours until surgical repair of penile fractures.** *Urol Int.* 2011; **87**(1): 75–9. [PubMed Abstract](#) | [Publisher Full Text](#)
- Nasser TA, Mostafa T: **Delayed surgical repair of penile fracture under local anesthesia.** *J Sex Med.* 2008; **5**(10): 2464–9. [PubMed Abstract](#) | [Publisher Full Text](#)
- Dhillan R, Sen D: **Emergency surgical management of double penile fracture at a peripheral hospital.** *Med J Armed Forces India.* 2015; **71**(Suppl 1): S46–8. [PubMed Abstract](#) | [Publisher Full Text](#) | [Free Full Text](#)
- Boncher NA, Vricella GJ, Jankowski JT, et al.: **Penile fracture with associated urethral rupture.** *Case Rep Med.* 2010; **2010**: 791948. [citado 9 de octubre de 2018]. [PubMed Abstract](#) | [Publisher Full Text](#) | [Free Full Text](#)
- Zargooschi J: **Penile fracture in Kermanshah, Iran: report of 172 cases.** *J Urol.* 2000; **164**(2): 364–366. [PubMed Abstract](#) | [Publisher Full Text](#)
- Barros R, Schulze L, Ornellas AA, et al.: **Relationship between sexual position and severity of penile fracture.** *Int J Impot Res.* 2017; **29**(5): 207–9. [PubMed Abstract](#) | [Publisher Full Text](#)
- Blake SM, Bowley DMG, Dickinson A: **Fractured penis: another complication of sildenafil. 2.** [Reference Source](#)
- Bitsch M, Kromann-Andersen B, Schou J, et al.: **The elasticity and the tensile strength of tunica albuginea of the corpora cavernosa.** *J Urol.* 1990; **143**(3): 642–5. [PubMed Abstract](#) | [Publisher Full Text](#)
- Falcone M, Garaffa G, Castiglione F, et al.: **Current Management of Penile Fracture: An Up-to-Date Systematic Review.** *Sex Med Rev.* 2018; **6**(2): 253–60. [PubMed Abstract](#) | [Publisher Full Text](#)
- Chung CH, Szeto YK, Lai KK: **'Fracture' of the penis: a case series.** *Hong Kong Med J.* 2006; **12**(3): 197–200. [PubMed Abstract](#)
- Morey AF, Brandes S, Dugi DD, et al.: **Urotrauma: AUA guideline.** *J Urol.* 2014; **192**(2): 327–35. [PubMed Abstract](#) | [Publisher Full Text](#) | [Free Full Text](#)
- Naraynsingh V, Hariharan S, Goetz L, et al.: **Late delayed repair of fractured penis.** *J Androl.* 2010; **31**(2): 231–3. [PubMed Abstract](#) | [Publisher Full Text](#)
- Wong NC, Dason S, Bansal RK, et al.: **Can it wait? A systematic review of immediate vs. delayed surgical repair of penile fractures.** *Can Urol Assoc J.* 2017; **11**(1–2): 53–60. [PubMed Abstract](#) | [Publisher Full Text](#) | [Free Full Text](#)

Open Peer Review

Current Peer Review Status:  

Version 2

Reviewer Report 05 September 2019

<https://doi.org/10.5256/f1000research.21347.r52773>

© 2019 Trivedi S. This is an open access peer review report distributed under the terms of the [Creative Commons Attribution License](#), which permits unrestricted use, distribution, and reproduction in any medium, provided the original work is properly cited.



Sameer Trivedi 

Department of Urology, Institute of Medical Sciences, Banarus, India

The revised manuscript has addressed the concerns raised previously and appears suitable for indexing in its present form.

Competing Interests: No competing interests were disclosed.

Reviewer Expertise: Andrology, Uro-oncology, Endourology

I confirm that I have read this submission and believe that I have an appropriate level of expertise to confirm that it is of an acceptable scientific standard.

Version 1

Reviewer Report 04 June 2019

<https://doi.org/10.5256/f1000research.17983.r48955>

© 2019 Trivedi S. This is an open access peer review report distributed under the terms of the [Creative Commons Attribution License](#), which permits unrestricted use, distribution, and reproduction in any medium, provided the original work is properly cited.



Sameer Trivedi 

Department of Urology, Institute of Medical Sciences, Banarus, India

1. The article has few grammatical errors and needs better proof reading.
2. Authors fail to mention other aetiological factors like the practice of "Taqandan" in Middle Eastern countries.

3. Authors have stated that involvement of both cavernosa is uncommon in penile fractures but have failed to mention the incidence in absolute numbers.
4. The authors did not perform any radiological imaging study because of lack of resources. It implies that they would have preferred to perform some imaging procedure had the required resources been available. It would be interesting to know what imaging modality they would have preferred to use in such a clinical scenario.
5. The authors state that absence of urethral bleeding and voiding difficulties was an indicator of uncompromised urethra. However, it would be prudent to reiterate that both of these factors are not reliable in ruling out associated urethral injuries as an overlying clot can mask the urethral disruption. Even a retrograde urethrogram can be falsely normal in such settings. A high degree of suspicion, complete exposure of corpus spongiosum and use of intra-operative manoeuvres like urethral injection of methylene blue have been advocated to detect occult urethral injuries.
6. In discussion, authors have mentioned that there is no statistical difference in long-term outcomes of early versus delayed repair in patients without urethral involvement (Ref 14, 15). However, the quoted study by Naraynsingh et al (ref 14) is a case report, without any statistical analysis.
7. In conclusion, authors have stated that imaging should be used to delineate the location and extent of the injury. However, as per both AUA and EAU guidelines, role of imaging is largely limited to unclear cases with equivocal findings or unreliable history (Ref below in citations).

References

1. Kitrey ND, Djakovic N, Kuehhas FE: European Association of Urology Guidelines on Urological Trauma. *European Association of Urology*. 2018. [Reference Source](#)
2. Morey AF, Brandes S, Dugi DD, Armstrong JH, et al.: Urotrauma: AUA guideline. *J Urol*. 2014; **192** (2): 327-35 [PubMed Abstract](#) | [Publisher Full Text](#)

Is the background of the case's history and progression described in sufficient detail?

Yes

Are enough details provided of any physical examination and diagnostic tests, treatment given and outcomes?

Partly

Is sufficient discussion included of the importance of the findings and their relevance to future understanding of disease processes, diagnosis or treatment?

Partly

Is the case presented with sufficient detail to be useful for other practitioners?

Yes

Competing Interests: No competing interests were disclosed.

Reviewer Expertise: Andrology, Uro-oncology, Endourology

I confirm that I have read this submission and believe that I have an appropriate level of expertise to confirm that it is of an acceptable scientific standard, however I have significant reservations, as outlined above.

Reviewer Report 25 April 2019

<https://doi.org/10.5256/f1000research.17983.r46660>

© 2019 Barros R. This is an open access peer review report distributed under the terms of the [Creative Commons Attribution License](#), which permits unrestricted use, distribution, and reproduction in any medium, provided the original work is properly cited.



Rodrigo Barros 

Hospital Municipal Souza Aguiar, Rio de Janeiro, Brazil

This article describes a case of complex penile fracture (PF) with bilateral corpus cavernosum involvement resulting from sexual activity. Sexual intercourse represents the main cause of PF and is usually associated with high-energy traumas causing double fractures. This may occur during more vigorous sexual intercourse, especially in certain positions. According to our previous study, “doggy style” position was most frequently associated with complex PF, second only to the “man-on-top” position. Differently from this case report, in our sample, the “woman-on-top” position showed a low incidence, and no significant association with the severity of the PF. The authors should mention some aspects that can lead to complex bilateral lesions, such as vigorous sexual intercourse and certain types of sexual positions.

Is the background of the case’s history and progression described in sufficient detail?

Yes

Are enough details provided of any physical examination and diagnostic tests, treatment given and outcomes?

Yes

Is sufficient discussion included of the importance of the findings and their relevance to future understanding of disease processes, diagnosis or treatment?

Partly

Is the case presented with sufficient detail to be useful for other practitioners?

Yes

Competing Interests: No competing interests were disclosed.

Reviewer Expertise: Sexual medicine

I confirm that I have read this submission and believe that I have an appropriate level of expertise to confirm that it is of an acceptable scientific standard.

The benefits of publishing with F1000Research:

- Your article is published within days, with no editorial bias
- You can publish traditional articles, null/negative results, case reports, data notes and more
- The peer review process is transparent and collaborative
- Your article is indexed in PubMed after passing peer review
- Dedicated customer support at every stage

For pre-submission enquiries, contact research@f1000.com

F1000Research