

Original Article

A 20-year experience in unilateral cleft lip repair: From Millard to the triple unilimb Z-plasty technique

Percy Rossell-Perry^{1,2}

¹Faculty of Human Medicine, Post Graduate Studies San Martin de Porres University, Lima, Peru, ²Outreach Surgical Center Lima Perú ReSurge International 145 N Wolfe Rd, Sunnyvale, CA 94086, USA

Address for correspondence: Dr. Percy Rossell-Perry, Schell St. No. 120 Apt. 1503 Miraflores, Lima 18, Peru.
E-mail: prossellperry@gmail.com

ABSTRACT

Background: This study describes a 20-year experience of treating patients with unilateral cleft lip. During this time, various techniques were used including Millard's technique and its modification and two types of geometrically designed procedures. The study objective was to compare surgical outcomes of different surgical techniques for unilateral cleft lip repair. **Materials and Methods:** This is a retrospective audit of outcomes after unilateral cleft lip repair performed by a single surgeon since 1995. Of the 827 patients who underwent surgery, 277 met the criterion of having anthropometric measurements performed ≥ 1 year postoperatively. The patients were stratified into three groups according to cleft severity: incomplete, complete with less deficiency (3–6 mm difference between cleft and non-cleft lip height) and complete with more deficiency (>6 mm difference between cleft and non-cleft lip height). Anthropometric measurements, scar assessment and complications were recorded. **Results:** There were no differences in outcomes between Millard and Reichert-Millard techniques for incomplete unilateral cleft lip. For complete unilateral cleft lip and less tissue deficiency, lip symmetry was better using upper rotation advancement plus double unilimb Z-plasty than the Reichert-Millard technique. For complete unilateral cleft lip and more tissue deficiency, lip symmetry was better after triple unilimb Z-plasty than after upper rotation advancement plus double unilimb Z-plasty. **Conclusions:** We presented a 20-year experience performing unilateral cleft lip repair. An individualised classification system with corresponding surgical techniques was successfully used during this period. The individualised surgical protocol used in this study allowed us to achieve improved surgical outcomes.

KEY WORDS

Cleft lip repair; millard technique; unilateral cleft lip

Access this article online	
Quick Response Code: 	Website: www.ijps.org
	DOI: 10.4103/0970-0358.197226

This is an open access article distributed under the terms of the Creative Commons Attribution-NonCommercial-ShareAlike 3.0 License, which allows others to remix, tweak, and build upon the work non-commercially, as long as the author is credited and the new creations are licensed under the identical terms.

For reprints contact: reprints@medknow.com

How to cite this article: Rossell-Perry P. A 20-year experience in unilateral cleft lip repair: From Millard to the triple unilimb Z-plasty technique. Indian J Plast Surg 2016;49:340-9.

BACKGROUND

This paper describes the author's experience over a 20-year period of treating patients with unilateral cleft lip. During the initial years, Millard's technique^[1] was used, but it produced variable results. Undesirable outcomes using this technique were primarily observed in patients with complete unilateral cleft lip. A modification (termed the Reichert-Millard technique by the author^[2]) was subsequently used, but this was accompanied by similar short-comings [Figures 1 and 2]. Both techniques were used initially for any type of cleft lip although the Reichert-Millard's technique was subsequently used only for those patients with incomplete cleft lip defects.

Six years later, a modification of Nakajima's concept^[3] was introduced to improve surgical outcomes in patients with complete unilateral cleft lip. This technique involved single upper rotation advancement and double lower

unilimb Z-plasties; however, limitations were observed in patients with deficient tissue [Figures 3 and 4]. To overcome these limitations, the author developed a new technique (initially called upper double rotation advancement)^[4,5] in 2007 to repair complete unilateral cleft lip defects in patients with deficient tissue in the lateral segment [Figures 5 and 6]. The technique has been used with great success in these difficult situations. It has subsequently been renamed triple unilimb Z-plasty because an additional Z-plasty is used.

In 2005, during the CLEFT 2005 Conference in Durban, South Africa, the author presented his cleft lip and palate classification using an innovative diagram known as the "clock diagram,"^[6,7] which considers four basic elements of the cleft deformity for secondary cleft palate,^[8] as well as a cleft code based on these elements. The four elements are the medial lip segment, lateral lip segment, cleft width and palatal index. We previously reported

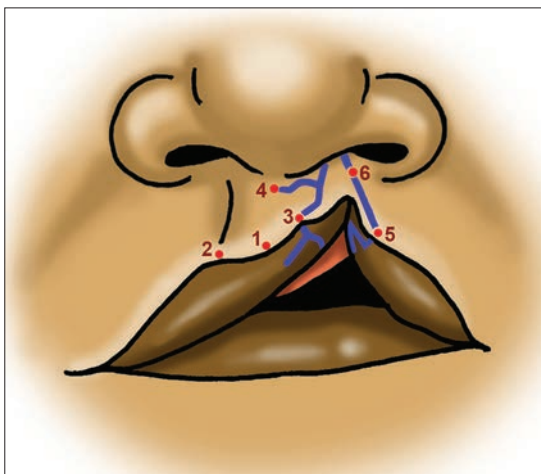


Figure 1: The Reichert-Millard technique (preoperative view)

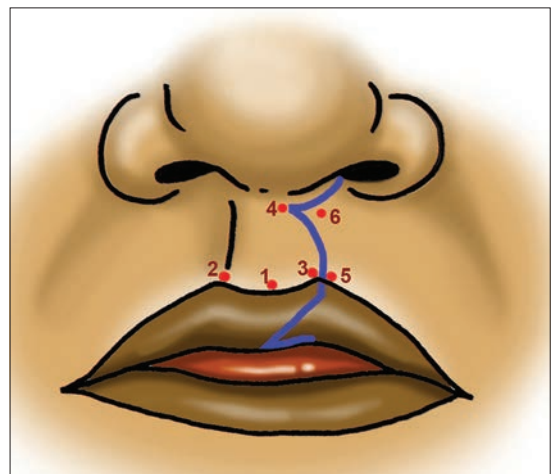


Figure 2: The Reichert-Millard technique (postoperative view)

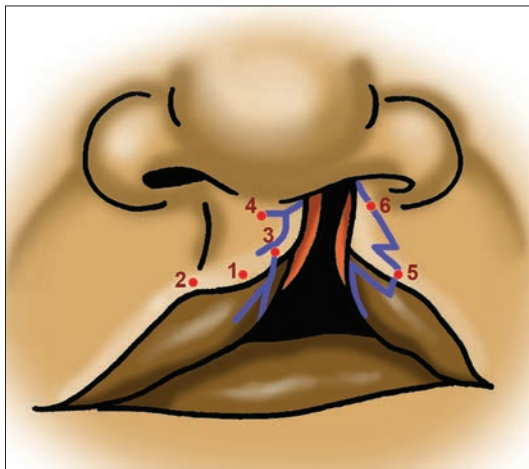


Figure 3: The upper rotation advancement plus double unilimb Z-plasty technique. (Preoperative view)

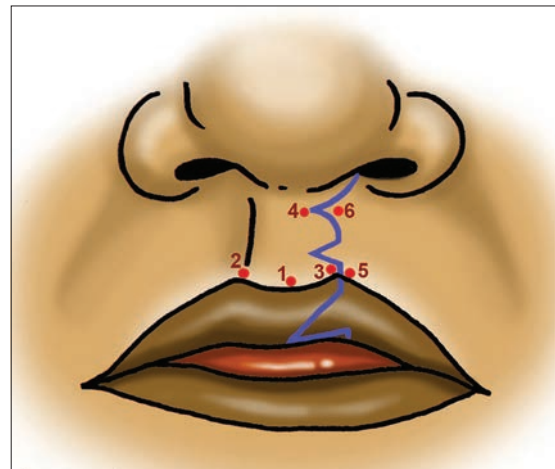


Figure 4: The upper rotation advancement plus double unilimb Z-plasty technique. (Postoperative view)

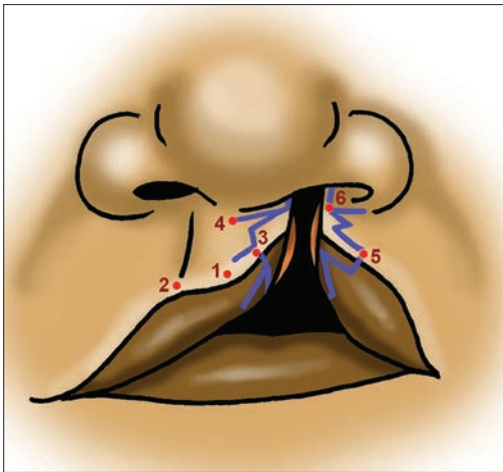


Figure 5: The triple unilimb Z-plasty technique. (Preoperative view)

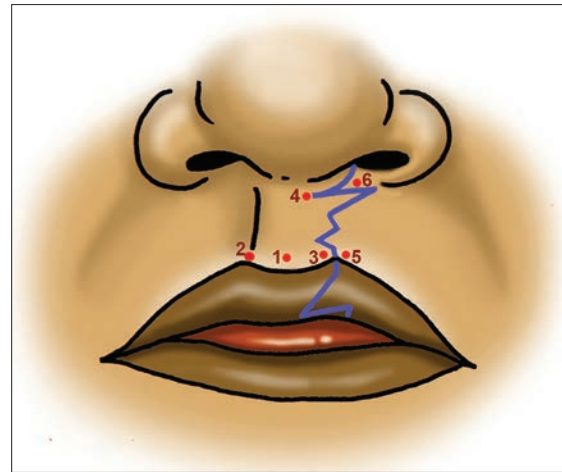


Figure 6: The triple unilimb Z-plasty technique. (Postoperative view)

improved surgical outcomes using an individualised protocol based on this classification system.^[9]

The objective of this study was to compare lip symmetry after using different surgical techniques for unilateral cleft lip repair in the author's practice over the last 20 years.

MATERIALS AND METHODS

This is a retrospective audit of outcomes of patients who underwent unilateral cleft lip repair by the author since 1995.

Of the 827 patients who underwent surgery during this time, 277 met the study inclusion criteria: non-syndromic unilateral cleft lip, operated upon at 3 months of age (as per our surgical protocol) and anthropometric measurements performed 1 year or later after surgery. The study protocol was approved by our Ethics Committee, and parents of each patient were informed of the nature of the surgical techniques used and granted signed consent before surgery.

Study groups

The patients were stratified into three groups based on the degree of tissue deficiency (reflecting the severity of the cleft lip defect).

Group A: Patients with mild tissue deficiency

Mild deficiency was defined as a <3 mm difference between the cleft and non-cleft lip height. All forms of incomplete unilateral cleft lips were included in this group. The Millard or Reichert-Millard techniques were used for lip repair in this group.

Group B: Patients with moderate tissue deficiency

Moderate deficiency was defined as a 3 to 6 mm difference between the cleft and non-cleft lip height. All of these patients had complete unilateral cleft lips. The Reichert-Millard or upper rotation advancement plus double unilimb Z-plasty techniques were used for lip repair in this group.

Group C: Patients with severe tissue deficiency

Severe deficiency was defined as a >6 mm difference between the cleft and non-cleft lip height. All of these patients had complete unilateral cleft lips. Upper rotation advancement plus double unilimb Z-plasty or triple unilimb Z-plasty techniques were used for lip repair in this group.

I did not compare Millard cases with triple unilimb Z-plasty technique to avoid bias in the study related to the learning curve of the surgeon.

Outcome assessment

All complete unilateral cleft lip measurements were done by physical examination under general anaesthesia using the Castroviejo calliper.

For incomplete cases, some were evaluated awake when this was possible and others during dental procedures or surgeries such as lingual frenulum release under general anaesthesia.

All the postoperative measurements were carried out between 1.5 and 2 years old. Surgical outcomes of the different surgical techniques were evaluated by comparing anthropometric measurements of the

upper lip. Measurements of the lip height, lip width, vermilion height alar base width were performed on the cleft side and non-cleft side 1 year or later after cleft lip repair. The standard measurements [Figure 7] are as follows.

Lip height

It refers to the distance from each peak of the Cupid's bow to a line tangent to the base of the columella.

Lip width

It refers to the distance measured from the Cupid's bow peak to the ipsilateral commissure.

Vermilion height

It refers to the distance from each peak of the Cupid's bow to a line across the red line of the lip.

Alar base width

It refers to the line measured from the midway point at the base of the columella to the most lateral point of the ala in a line perpendicular to the axis of the columella.

Surgical techniques

The surgical techniques used by the author are described in the cited papers and illustrated in Figures 1-6 and 8-13.

Reichert-Millard technique

This is a Millard's modification technique and uses the same concept (medial rotation and lateral advancement) with less surgical incisions (avoids sub-nasal incision).^[2]

The surgical incisions are illustrated in Figure 1.

Medial segment

A curve full-thickness incision is done at the mucocutaneous junction of the cleft margin up to the

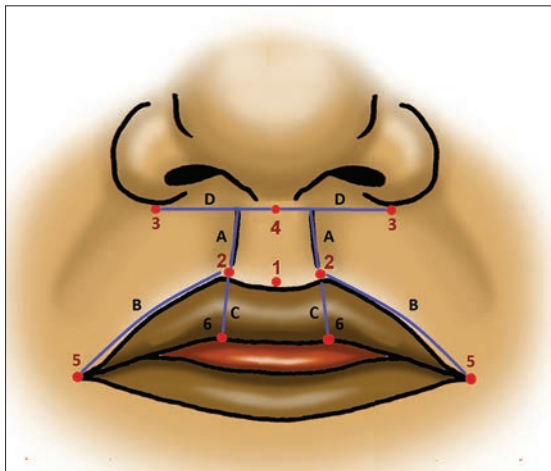


Figure 7: Standard anthropometric measurements. 1: Cupid's bow middle point. 2: Peak of Cupid's bow. 3: Alar base. 4: Columellar base middle point. 5: Lip commissure. 6: Red line. (A) Lip height. (B) Lip width. (C) Vermilion height. (D) Alar base width

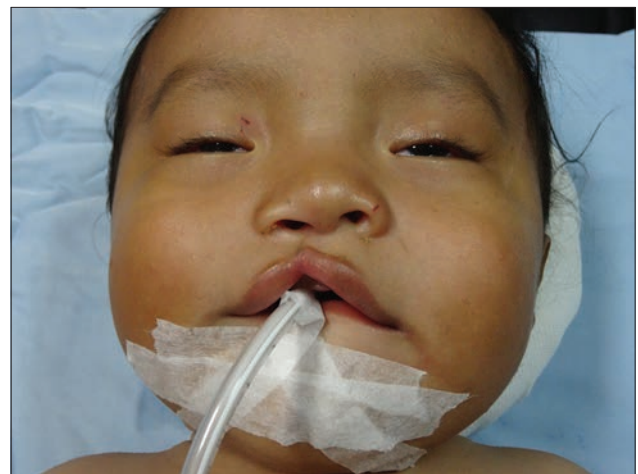

Figure 8: Pre-operative view of a 3-month-old patient with incomplete unilateral cleft lip

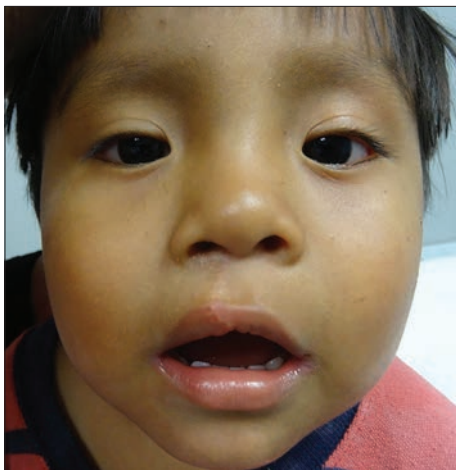

Figure 9: Post-operative view of the patient (2 years old) shown in Figure 7 after undergoing repair using the Reichert-Millard technique

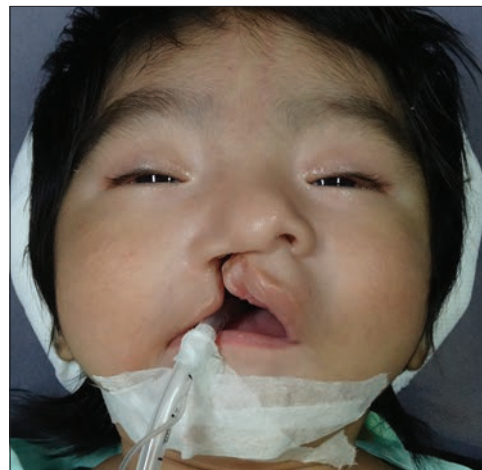

Figure 10: Pre-operative view of a 3-month-old patient with complete unilateral cleft lip and moderate tissue deficiency

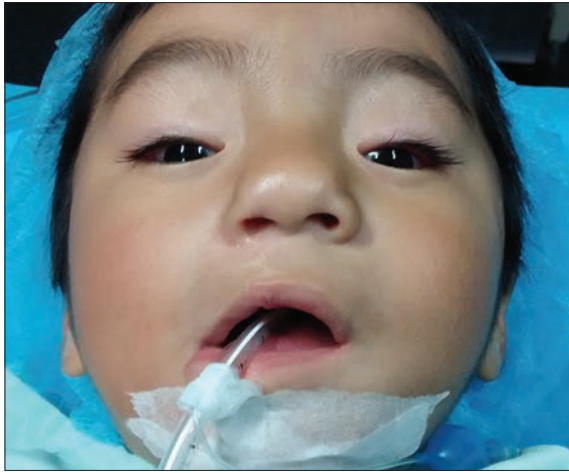

Figure 11: Post-operative view of the patient (1.5 years old) shown in Figure 9 after undergoing repair using the upper rotation advancement plus double unilimb Z-plasty technique

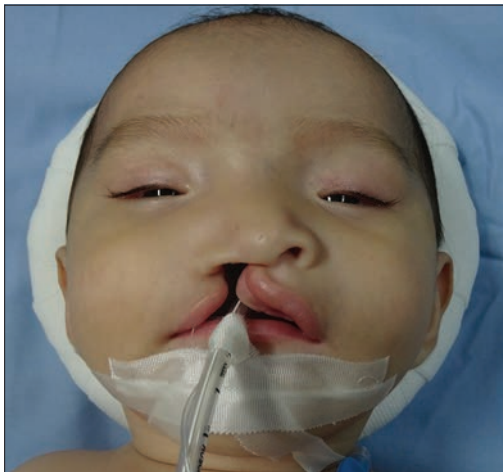

Figure 12: Pre-operative view of a 3-month-old patient with complete unilateral cleft lip and severe tissue deficiency

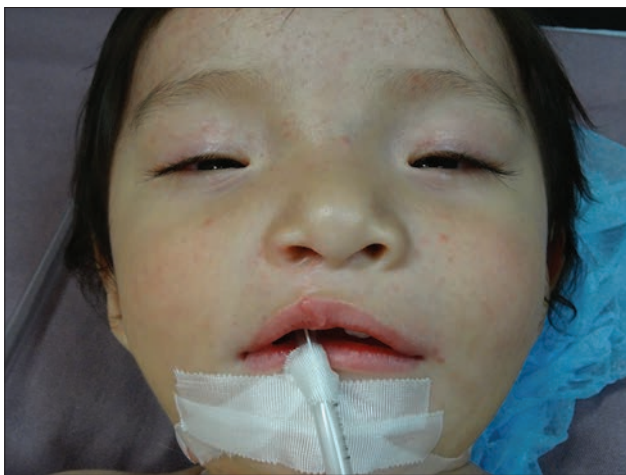

Figure 13: Post-operative view of the patient (1.5 years old) shown in Figure 11 after undergoing repair using the triple unilimb Z-plasty technique

base of the columella, following the proposed design. Then, the medial lip segment is lowered to such a

position that the height of the Cupid's bow is equal on both sides.

Lateral segment

A similar incision is performed at the mucocutaneous junction of the cleft margin starting just where the white roll ends and continues inside the nose toward the pyriform aperture.

Then, the muscle is released from the abnormal insertion in both sides and turns it down. Muscle and lip mucosa are closed in a border to border form.

The skin closure is performed following the diagram in Figure 2.

Upper rotation advancement and double lower unilimb Z-plasty

This technique is a modification of the Nakajima's concept. It uses an upper rotation advancement and two unilimb Z-plasties.^[3]

The surgical incisions are illustrated in Figure 3. The medial lip full thickness incision leaves two rotations: upper (below the columella) and lower (above the white roll). Additional rotational incision is done at the red line level.

The lateral lip incision starts just where the white roll ends and creates a lower triangle (above the white roll) and one advancement flap (similar to the Reichert-Millard's lateral flap) in the upper position [Figure 3].

This incision continues over the vermillion and ends designing a small triangle. Muscles are released from both sides and closed in a border to border form.

Skin closure is finally done obtaining a proper lip length using one rotation advancement and 2 unilimb Z-plasties [Figure 4].

Triple unilimb Z-plasty

This technique is based on 3 unilimb Z-plasties and was created to be used in severe forms of complete unilateral cleft lips.^[4,5]

The surgical incisions are illustrated in Figure 5. Medial lip incision is done making a lower rotation (above the white roll) and an upper small triangle below the columella [Figure 5]. After this, an appropriate downward rotation of the Cupid's bow is completed in 2

levels. Additional rotational incision is performed at the vermilion (red line level).

Lateral lip incision starts just where the white roll ends and is made leaving a lower small triangle (lower lip) and upper rotational incision at the sub-nasal level [Figure 5].

The incision continues over the vermilion designing a small triangle. Then, the muscle is released from the abnormal insertion in both sides and turns it down. Muscle and lip mucosa are closed in a border to border form.

The skin closure is done following the diagram in Figure 6. This is based on three unilimb Z-plasties.

There were not differences in surgical treatment between the used techniques with the exception of the skin incisions.

The cleft palate repair was done around 1.5 years old using a single stage.

In all patients, silicone gel was applied over the lip scar 3 weeks after surgery and continued for the next 3 months.

No patient underwent infiltration of the surgical area with corticosteroids.

Primary rhinoplasty

Primary rhinoplasty was performed in all patients using the technique described by Potter^[10] (a composite V-Y advancement flap was used to correct the nose deformity) and then by Cronin *et al.*^[11] This technique allowed us to reposition the nose cartilages and lengthen the nasal vestibule with good results.

Skin incisions along the marginal and inter-cartilaginous borders are performed creating a composite flap (vestibular skin and alar cartilage) in a V form.

Alar cartilages are then de-gloved at the nasal tip level. Later, the mentioned flap is displaced medially and the surgical wound closed in a V-Y form.

All the incisions are closed using transcutaneous stitches limiting the space created by the nasal dissection.

Alveolar cleft repair

The alveolar cleft was repaired in two stages. During the first stage (after 5 years of age), we closed the alveolar

cleft using alveolar mucoperiosteal advancement flaps. The second stage was performed during the mixed dentition period using a small incision to create a pocket where the cancellous bone graft was placed.

Statistical analysis

The Z-test of proportions and the Wilcoxon-signed rank test were used to evaluate the characteristics of the studied patients.

The paired *t*-test was used to analyse surgical outcomes. For statistical significance, the alpha error was set at ≤ 0.05 .

All confidence intervals were expressed as 95%. Standard software (SPSS v15.0; SPSS Inc., Chicago, IL, USA) was utilised for all data analysis.

RESULTS

Demographic and other characteristics (number, age, gender, type of cleft and cleft width) of the 277 patients included in this study are presented in Table 1.

In Group A patients (mild tissue deficiency), no statistically significant difference was observed between the cleft side and non-cleft side for lip height, lip width, vermilion height or nasal base width using the Millard or Reichert-Millard techniques, when evaluated at least 1-year postoperatively [Tables 2-3 and Figures 8-9].

In Group B patients (moderate tissue deficiency), statistically significant differences were observed between the cleft side and non-cleft side with regard to nasal base width, lip height and lip width using the Reichert-Millard technique, when evaluated at least 1-year postoperatively [Tables 2 and 3]. No statistically significant differences were observed between the cleft side and non-cleft side for vermilion height, lip height and lip width using the upper rotation advancement plus double unilimb Z-plasty technique. Statistically significant differences were observed in lip height and width of the cleft side between the two techniques. Better lip symmetry was achieved using the upper rotation advancement plus double unilimb Z-plasty technique [Tables 2-3 and Figures 10-11].

In Group C patients (severe tissue deficiency), statistically significant differences were observed between the cleft side and the non-cleft side for nasal base width, lip height

Table 1: Characteristics of the study patients with unilateral cleft lip (n=277)

	Group A			Group B			Group C				
	Technique 1	Technique 2	CL	Technique 3	Technique 4	P	CL	Technique 5	Technique 6	P	CL
n	62	65		44	40			30	36		
Gender*											
Male	34	41	0.401	24	23	0.817	0-0.13	18	23	0.618	0-0.21
Female	28	24		20	17			12	14		
Cleft side*											
Right	21	25	0.645	19	15	0.590	0-0.20	11	13	0.442	0-0.30
Left	41	40		25	25			19	23		
Cleft width**				4.151 (0.544)	4.115 (0.590)	0.445	-0.5812-0.9507	4.833 (0.617)	5.231 (0.219)	0.212	-2.2192-1.1906

*Z test of proportions, **Wilcoxon signed rank test. Mean (SD). SD: Standard deviation, CL: Confidence level

and lip width using the upper rotation advancement plus double unilimb Z-plasty technique when evaluated at least 1-year postoperatively [Tables 2 and 3]. No statistically significant differences were observed between sides for vermilion height and lip height using the triple unilimb Z-plasty technique. Statistically significant differences were observed for lip height and width on the cleft side between the two techniques. Better lip symmetry was obtained using the triple unilimb Z-plasty [Tables 2-3 and Figures 12-13].

DISCUSSION

Although some previous studies^[12,13] have indicated that outcomes do not differ between surgical techniques for unilateral cleft lip repair, and this study provides evidence suggesting that outcomes may be different.

Millard's technique and related methods are still common procedures. A recent survey conducted by Sitzman *et al.*^[14] in the United States and Canada observed that 84% of surgeons perform rotation advancement techniques for complete unilateral cleft lip. However, various short-comings of this technique have been reported.^[15-17]

The presented results suggest that rotation advancement techniques have limited effectiveness when used to correct complete unilateral cleft lips. This can be explained by the inability of Millard's method to properly lengthen the lateral segment. Complete unilateral cleft lips have more tissue deficiency and require lengthening of both the medial and lateral segments. Rotation advancement techniques are useful for patients with mild tissue deficiency (mostly incomplete cleft lips). In these instances, the lateral segment can be advanced without major lengthening.

The Reichert-Millard technique lets us obtain surgical outcomes that are similar to those achieved with Millard's method, but the Reichert-Millard technique (described by the author in 2008)^[2] requires fewer surgical incisions than Millard's method. The sub-nasal incision is eliminated. We observed good surgical outcomes using this technique in patients with incomplete cleft lip.^[2]

Lip height can be increased using rotation advancement techniques, but lip width is usually compromised. The importance of preserving lip width has been emphasised by Losee *et al.*^[18] and Fisher.^[19] We definitely agree

Table 2: Comparisons of non-cleft and cleft side using different techniques. Outreach Surgical Center Program Lima Peru (n=277)

Lip measurements	Group A					
	Technique 1 (n=62)			Technique 2 (n=65)		
	Non-cleft mean (SD)	Cleft mean (SD)	P	Non-cleft mean (SD)	Cleft mean (SD)	P
Lip height	11.75806 (1.147849)	11.48387 (1.086307)	0.255	11.66761 (1.106749)	11.31633 (1.178515)	0.135
Vermillion height	4.45082 (0.693451)	4.51639 (0.816329)	0.305	4.31675 (0.631211)	4.28949 (0.816036)	0.469
Lip width	14.89344 (1.061111)	14.64754 (1.205350)	0.198	14.72825 (1.150983)	14.50087 (1.297829)	0.324
Nasal base width	14.39344 (1.231918)	14.58197 (1.363758)	0.106	14.31635 (1.278888)	14.48129 (1.385307)	0.808
Lip measurements	Group B					
Lip measurements	Group B					
	Technique 3 (n=44)			Technique 4 (n=40)		
	Non-cleft mean (SD)	Cleft mean (SD)	P	Non-cleft mean (SD)	Cleft mean (SD)	P
Lip height	11.59138 (1.195408)	10.62520 (1.180417)	0.0001	11.7125 (1.120254)	11.3125 (1.152964)	0.123
Vermillion height	4.21735 (0.651858)	4.15654 (0.656180)	0.137	4.2752 (0.6788943)	4.2211 (0.723240)	0.262
Lip width	14.56321 (1.123128)	13.56858 (1.180568)	0.0001	14.7751 (1.120611)	14.5752 (1.118321)	0.994
Nasal base width	13.89718 (1.179221)	15.12140 (1.665826)	0.0001	13.9510 (1.159133)	14.71110 (1.385826)	0.0001
Lip measurements	Group C					
Lip measurements	Group C					
	Technique 5 (n=30)			Technique 6 (n=36)		
	Non-cleft mean (SD)	Cleft mean (SD)	P	Non-cleft mean (SD)	Cleft mean (SD)	P
Lip height	11.43509 (1.234590)	10.31667 (1.004158)	0.0001	11.6847 (1.155885)	11.2261 (1.157207)	0.376
Vermillion height	4.33215 (0.791477)	4.44001 (0.723973)	0.546	4.3814 (0.796501)	4.4567 (0.895658)	0.275
Lip width	13.91379 (1.118585)	12.56897 (1.200626)	0.0001	14.72240 (0.818822)	13.47552 (1.112269)	0.0001
Nasal base width	13.75421 (1.095445)	14.93333 (1.304722)	0.0001	13.88681 (1.017801)	14.68173 (1.411311)	0.005
						-1.161311- -0.543215

SD: Standard deviation, CL: Confidence level

Table 3: Comparison using difference techniques. Outreach Surgical Center Program Lima Peru (n=277)

Lip measurements	Group A			
	Mean (SD)		P	CL
	Technique 1	Technique 2		
Lip height	11.48387 (1.086307)	11.31633 (1.178515)	0.836	-0.1291527-0.727011
Lip width	14.64754 (1.205350)	14.50087 (1.297829)	0.915	-0.040434-0.1372082
Lip measurements	Group B			
	Mean (SD)		P	CL
	Technique 3	Technique 4		
Lip height	10.62520 (1.180417)	11.3125 (1.152964)	0.001	-1.616554--0.2915541
Lip width	13.56858 (1.180568)	14.5752 (1.118321)	0.0001	-0.849990--0.400009
Lip measurements	Group C			
	Mean (SD)		P	CL
	Technique 5	Technique 6		
Lip height	10.31667 (1.004158)	11.2261 (1.157207)	0.0001	-0.8414495--0.3752172
Lip width	12.56897 (1.200626)	13.47552 (1.112269)	0.0001	-1.1509161--0.4990836

SD: Standard deviation, CL: Confidence level

with Loose *et al.* when they stated that marking the height of the Cupid’s bow on the lateral lip segment should be performed just before the attenuation of lip fullness (where the white roll ends) and not before the white roll ends as Noordhoof described.^[20] The width of the lateral lip segment is shorter in complete clefts and should be preserved as much as possible to obtain lip symmetry. After comparing the Reichert-Millard and upper rotation advancement plus double unilimb Z-plasty techniques, we observed a shorter width of the lateral lip segment using the rotation-advancement method. This same disadvantage has been previously described by Fisher.^[19] Based on our results, Z-plasties therefore appear to be necessary to provide proper lip height without compromising lip width in patients with complete cleft lip.

During the first 10 years encompassed within this study, the surgical techniques allowed us to achieve lip symmetry in patients with unilateral cleft lip with mild tissue deficiency, but they were limited in their ability to provide good surgical outcomes in patients with more extensive tissue deficiency. We observed this limitation primarily in those patients with severe tissue deficiency (>6 mm difference between the cleft and non-cleft lip height). The upper rotation advancement plus double unilimb Z-plasty has a limited ability to properly repair these cleft lips since there is insufficient lip tissue at the lateral lip segment for lip lengthening.

The triple unilimb Z-plasty procedure is an innovative technique described by the author^[4,5] that allows the surgeon to increase the height of the lateral lip segment

using skin from the medial segment (which is usually not used during the other techniques).

Our current results demonstrate the efficacy of this technique in addressing defects with greater tissue deficiency. The main advantage of this technique is the preservation of lip tissues, which is why the method is successful when the availability of tissues is limited. The upper and lower triangles are small (3 mm wide) and most of the incisions are located between the aesthetic subunits of the upper lip. In a previous study,^[4] we did not observe differences in lip width between the cleft lip and non-cleft lip sides after surgery using the triple unilimb Z-plasty technique; however, patients with more tissue deficiency have a short lateral lip segment that cannot be improved by any surgical technique. The results obtained in our previous study can be explained by the inclusion of both moderate and severe unilateral cleft lips in that study.

In relation to the cleft lip nose deformity, any type of primary rhinoplasty is an incomplete repair since we are not repairing the skeleton deformity primarily. Although some surgical outcomes are acceptable, most patients require surgical correction at a later age, and the rate of nose revision is usually high.

We did not use any specific type of presurgical management such as naso-alveolar moulding for the patients included in this study.

Two systematic reviews have described the absence of scientific evidence supporting the use of naso-alveolar moulding for patients undergoing unilateral cleft lip repair.^[21,22]

The main limitation of this study could be a degree of selection bias since the criteria used to enrol patients into separate groups are different (cleft's severity protocol).

Another limitation is the use of single observer to evaluate the surgical outcomes.

It is very difficult to maintain the same team of observers during long time (20 years) and would introduce bias to the outcome evaluation if we use too many observers.

CONCLUSIONS

This study described the author's experience performing unilateral cleft lip repair over a 20-year period. An individualised classification system with corresponding surgical techniques was used successfully during this period. Based on our results, we suggest that the surgical technique should be selected according to the severity of the unilateral cleft lip defect. The individualised surgical protocol used in this study allowed us to obtain improved lip symmetry after unilateral cleft lip repair.

Declaration of patient consent

The authors certify that they have obtained all appropriate patient consent forms. In the form the patient(s) has/have given his/her/their consent for his/her/their images and other clinical information to be reported in the journal. The patients understand that their names and initials will not be published and due efforts will be made to conceal their identity, but anonymity cannot be guaranteed.

Financial support and sponsorship

Nil.

Conflicts of interest

There are no conflicts of interest.

REFERENCES

1. Millard R Jr. A primary camouflage of the unilateral hare-lip. In: Transactions of the International Society of Plastic Surgeons. Baltimore: Williams and Wilkins; 1957:160-6.
2. Rossell-Perry P. Modification of Reichert's technique based on natural landmarks and individual designs for unilateral repair of cleft lip. *Scand J Plast Reconstr Surg Hand Surg* 2008;42:113-21.
3. Nakajima T, Yoshimura Y, Yoneda K, Nakanishi Y. Primary repair of an incomplete unilateral cleft lip: Avoiding an elongated lip and achieving a straight suture line. *Br J Plast Surg* 1998;51:511-6.
4. Rossell-Perry P, Gavino-Gutierrez AM. Upper double-rotation advancement method for unilateral cleft lip repair of severe forms: Classification and surgical technique. *J Craniofac Surg* 2011;22:2036-42.
5. Rossell-Perry P, Cotrina-Rabanal O. Surgical technique for unilateral cleft lip repair with short lateral segment, Peruvian Medical Archives 2010;28:168-76.
6. Rossell-Perry P. Book of Abstracts. Presented at the 10th International Congress on Cleft Lip and Palate and Related Craniofacial Anomalies, Durban, South Africa; 6th September, 2005.
7. Rossell-Perry P. New diagram for cleft lip and palate description: The clock diagram. *Cleft Palate Craniofac J* 2009;46:305-13.
8. Rossell-Perry P, Caceres Nano E, Gavino-Gutierrez AM. Association between palatal index and cleft palate repair outcomes in patients with complete unilateral cleft lip and palate. *JAMA Facial Plast Surg* 2014;16:206-10.
9. Rossell-Perry P, Gavino-Gutierrez A. New perspective in congenital cleft lip surgical management. *Ibero Latin American Plastic Surgery Journal* 2013;39:23-34.
10. Potter J. Some nasal tip deformities due to alar cartilage abnormalities. *Plast Reconstr Surg* 1954;13:358-66.
11. Cronin ED, Rafols FJ, Shayani P, Al-Haj I. Primary cleft nasal repair: The composite V-Y flap with extended mucosal tab. *Ann Plast Surg* 2004;53:102-8.
12. Demke JC, Tatum SA. Analysis and evolution of rotation principles in unilateral cleft lip repair. *J Plast Reconstr Aesthet Surg* 2011;64:313-8.
13. Reddy GS, Webb RM, Reddy RR, Reddy LV, Thomas P, Markus AF. Choice of incision for primary repair of unilateral complete cleft lip: A comparative study of outcomes in 796 patients. *Plast Reconstr Surg* 2008;121:932-40.
14. Sitzman TJ, Giroto JA, Marcus JR. Current surgical practices in cleft care: Unilateral cleft lip repair. *Plast Reconstr Surg* 2008;121:261e-70e.
15. Holtmann B, Wray RC. A randomized comparison of triangular and rotation-advancement unilateral cleft lip repairs. *Plast Reconstr Surg* 1983;71:172-9.
16. Chowdri NA, Darzi MA, Ashraf MM. A comparative study of surgical results with rotation-advancement and triangular flap techniques in unilateral cleft lip. *Br J Plast Surg* 1990;43:551-6.
17. Lazarus DD, Hudson DA, van Zyl JE, Fleming AN, Fernandes D. Repair of unilateral cleft lip: A comparison of five techniques. *Ann Plast Surg* 1998;41:587-94.
18. Losee JE, Selber JC, Arkoulakis N, Serletti JM. The cleft lateral lip element: Do traditional markings result in secondary deformities? *Ann Plast Surg* 2003;50:594-600.
19. Fisher DM. Unilateral cleft lip repair: An anatomical subunit approximation technique. *Plast Reconstr Surg* 2005;116:61-71.
20. Noordhoff S. The surgical technique for the unilateral cleft lip nasal deformity. Taipei: Noordhoff Craniofacial Foundation; 1997. p. 27-35.
21. van der Heijden P, Dijkstra PU, Stellingsma C, van der Laan BF, Korsten-Meijer AG, Goorhuis-Brouwer SM. Limited evidence for the effect of presurgical nasoalveolar molding in unilateral cleft on nasal symmetry: A call for unified research. *Plast Reconstr Surg* 2013;131:62e-71e.
22. Abbott MM, Meara JG. Nasoalveolar molding in cleft care: Is it efficacious? *Plast Reconstr Surg* 2012;130:659-66.