

## A comparative study of digital lateral radiography and virtual cone-beam computed assisted cephalogram in cephalometric measurements.

Jesica Calle-Morocho,<sup>1</sup> Rafael Morales-Vadillo,<sup>2</sup> Janet Guevara-Canales<sup>3</sup>  
& Carlos Alva-Cuneo.<sup>1</sup>

**Affiliations:** <sup>1</sup>Radiología Bucal y Maxilofacial, Universidad de San Martín de Porres, Lima, Perú. <sup>2</sup>Director del Instituto de Investigación de la Facultad de Odontología de la Universidad de San Martín de Porres, Lima, Perú. <sup>3</sup>Patología y Medicina Oral y Maxilofacial, Universidad de San Martín de Porres, Lima, Perú.

**Corresponding author:** Jesica Calle-Morocho. Avenida 24 de Mayo e Ingapirca, Cañar-Ecuador. E-mail: jescalle@gmail.com

**Receipt:** 05/14/2018 **Revised:** 06/11/2018  
**Acceptance:** 10/09/2018 **Online:** 11/28/2018

**Conflict of interests:** The authors declare no conflict of interests.

**Ethics approval:** The present study was approved by the Research Review Committee ACTA N ° 010-2017 (04/20/2017) and by the Committee of Research Ethics ACTA N ° 002-2017 (30 / 05/2017), from the Faculty of Dentistry of the University of San Martín de Porres, Lima, Perú.

**Funding:** Self-financed

**Authors' contributions:** This work was carried out in collaboration between all authors.

**Acknowledgements:** To the *Institute of Maxillofacial Diagnosis* and its director Dr. Andrés Agurto Huerta and to Dr. Sergio Samanamú Leandro.

**Cite as:** Calle-Morocho J, Morales-Vadillo R, Guevara-Canales J & Alva-Cuneo C. A comparative study of digital lateral radiography and virtual cone-beam computed assisted cephalogram in cephalometric measurements. *J Oral Res* 2018;7(8):372-381.  
doi:10.17126/joralres.2018.076

**Abstract:** Objectives: To assess discrepancies in cephalometric measurements from digital lateral radiography and virtual cone-beam computed assisted tomography cephalogram. Materials and methods: Forty digital lateral radiographs and forty virtual cephalograms obtained by cone-beam computed assisted tomography were analyzed, corresponding to forty patients from the *Instituto de Diagnóstico Maxilofacial* in Lima, Peru. The principal investigator, who had been previously calibrated, made two measurements within a timespan of fifteen days using the analysis of Steiner and the NemoCeph software, and the difference between the obtained measurements was evaluated to determine if it was significant. Results: For digital lateral radiographs the difference varied between 0.00° - 0.45° and 0.01mm - 0.16mm, with statistical significance for distance between Pg and NB for lateral virtual cephalograms between 0.03° - 0.73° and 0.01mm - 0.43mm, with statistical significance for SE distance. The comparison between the two types of image in the first measurement showed a difference of 0.08° - 1.15° and 0.00mm - 1.43mm with statistical significance for four angular measurements and one linear. The comparison between the two types of image in the second measurement showed a difference of 0.13° - 1° and 0.02mm - 1.32mm with a statistically significant difference for three angular and two linear measurements. Conclusions: The difference between the two types of image is minimal; both evaluated methods can be used effectively.

**Keywords:** Cone-Beam computed tomography; cephalometry; validity; reliability.

### INTRODUCTION.

Cephalometry is considered an essential tool for the diagnosis, planning, and the evaluation of craniofacial growth and development,<sup>1</sup> and as such part of the orthodontic documentation includes obtaining lateral cephalograms.<sup>2,3</sup> The ideal type of image for cephalometric studies has not yet been defined.<sup>3</sup> Commonly used image methods, such as lateral cephalometric radiography, despite its wide use in orthodontics, are subject to errors, basically of two types: projection errors and identification errors<sup>4</sup> which include the difficulty in identifying reference or anatomical points, mainly due to the superposition of structures, distortion and enlargement<sup>5</sup> when making hand-drawn measurements,<sup>6</sup> as well as a large amount of time consumed for evaluations.<sup>7</sup> New types of images obtained using Cone Beam Computed Tomography (CBCT) are emerging as an alternative to conventional lateral cephalometric radiography, however, it is necessary to validate the images generated using these technologies

in order to provide comparisons; that is, more studies should be done to compare conventional images with novel ones such as the lateral cephalogram obtained from CBCT, otherwise these new methods cannot be used to evaluate orthodontic therapies.<sup>3</sup> Authors such as Naoumova,<sup>7</sup> Chen<sup>8</sup> y Kusnoto<sup>9</sup> have compared the effectiveness of programs that perform evaluations of digitized cephalograms with manual tracing methods and concluded that using the digital method linear and angular measurements can be made efficiently. These results are not, however, unanimous in the literature.<sup>10,11</sup>

To minimize this type of errors of different magnitudes, new methods that reduce them to the minimum are sought, for which new technologies both for obtaining the image and for its analysis are emerging, with the aim of improving the quality of such evaluations.<sup>3</sup>

Since the change to digital methods is eminent,<sup>12</sup> professionals must be prepared so that the transition is carried out in the safest way possible.<sup>3</sup>

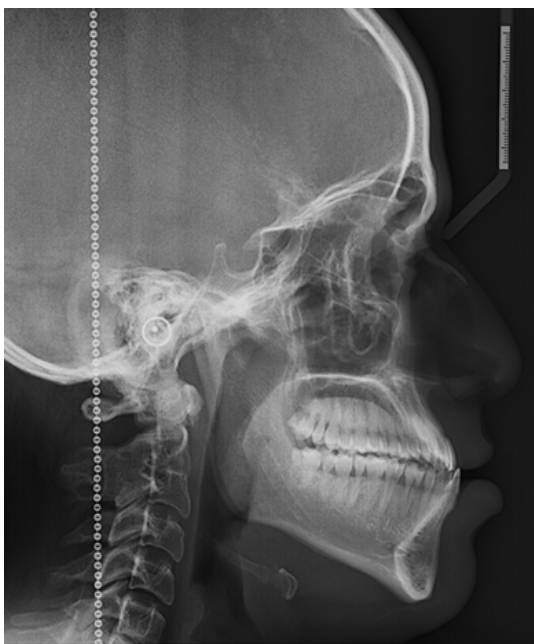
This will be achieved once all tools within modern CBCT software, that basically save time, and in some cases avoid unnecessary overexposure to the patient, are known and handled; from a CBCT scan all kinds of images can be obtained, for example rendering of panoramic, postero-anterior and lateral cephalometric

images (those used in this study) and in turn from these images the necessary assessment can be performed in each case. It is worth emphasizing the need for a justification for any type of radiation exposure, even more so when it comes to tomography, however, if after a thorough clinical examination and assessment by the professional a patient must undergo a CBCT scan (for example in cases of surgery) additional images can be obtained from it, with which, for example, cephalometric analysis would be performed, thus avoiding overexposure to the patient who would have undergone another imaging exploration to obtain a lateral cephalometric radiograph.

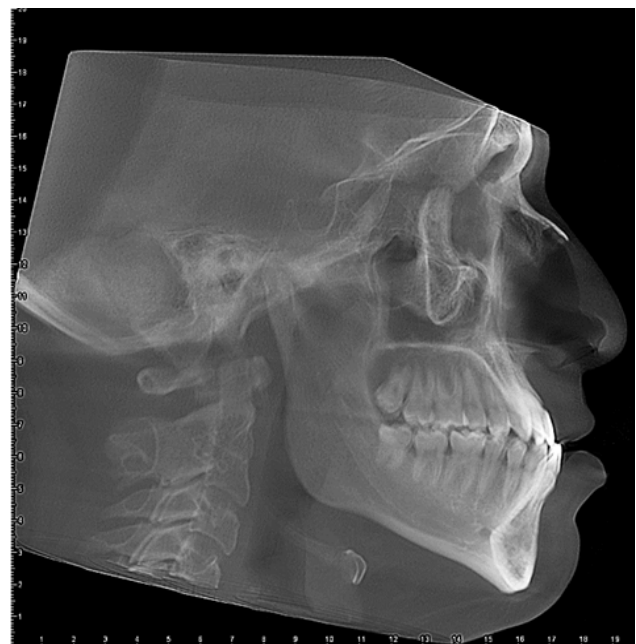The comparison of exams performed from digital images and those obtained from CBCT scans is fundamental, in order to achieve a transition from two-dimensional to three-dimensional methods,<sup>3</sup> which probably provides bias-free estimates that are closer to reality.

Before establishing the CBCT as a common approach in orthodontic diagnosis, its validity and reliability should be evaluated, therefore, the objective of this study was to determine the discrepancies of the cephalometric measurements made with digital lateral radiography and lateral virtual cephalogram from cone beam computed tomography.

**Figure 1:** Digital lateral radiograph.



**Figure 2:** Lateral cone beam computed tomography virtual cephalogram.



## MATERIALS AND METHODS.

The study design was observational, analytical, longitudinal and retrospective, with the protocol of this study evaluated by the Research Review Committee ACTA N°010-2017 and by the Research Ethics Committee ACTA N°002-2017, of the Faculty of Dentistry of the *Universidad de San Martín de Porres*.

Initially, a pilot study was carried out with the objective of calibrating the principal investigator in the most accurate location of the reference points used for the computerized Steiner cephalometric analysis from digital lateral radiographs and CBCT generated cephalograms. For this purpose, the sample consisted of 10 radiographs and 10 tomographies corresponding to 10 patients who met the following inclusion criteria: digital lateral cephalometric radiographs and large field tomographies of patients over 18 years of age and digital lateral cephalometric radiographs and large field tomographies with adequate visualization of anatomical structures related to the study area. Steiner's computerized cephalometric analysis was performed on the images obtained, analyzing 5 out of 14 measurements (SNA, SNB, interincisal angle, distanceSE, distance Pg-NB), to assess the agreement between observers (one was the principal investigator and the other a specialist in Oral and Maxillofacial Radiology); the intraclass correlation coefficient (ICC) was evaluated, the result was greater than 0.9, therefore, the agreement between the evaluators was "almost perfect". The sample was selected according to the accessibility, and personal and intentional criteria of the principal investigator. In addition, because the population was limited, randomization was impossible to perform; therefore, the selected sample was non-probabilistic for convenience. Finally, the study consisted of all digital lateral cephalometric radiographs and cone beam CT scans of the patients who were treated at the *Maxillofacial Diagnostic Institute* during 2016 who met the inclusion criteria. In total, 40 radiographs and 40 tomographies were studied (the cases that were used for the pilot study were not included).

Digital lateral cephalometric radiographs were obtained with a Planmeca ProMax 2D (Finland) with a kilovoltage of 70 to 76, milliamperage of 8 to 10 and exposure time of 8 to 10 seconds; for the patient's position the Frankfurt plane parallel to the floor was used; to avoid movement, the

head was stabilized using rods, all the images included a millimeter ruler that was used to calibrate the image when introducing it to the NemoCeph software. The digital images were stored in the Romexis computer database, version 3.6.0, Planmeca, Helsinki, Finland. The brightness and contrast were adjusted if necessary, then exported in JPEG format. (Figure 1)

Cone beam CT scans were obtained with Planmeca ProMax 3D Classic (Finland) with a kilovoltage of 90, milliamperage from 8 to 14, exposure time 14 seconds, image size 020.0 x 17.4cm and voxel size 400 $\mu$ m; the patient's head was in natural position, with the mouth closed and in maximum normal and natural intercuspitation, and they were requested to remain still throughout the imaging procedure. The digital images were stored in the Romexis computer database, version 3.6.0, Planmeca, Helsinki, Finland. To obtain the lateral cephalogram, the software has a virtual cephalogram option from which, from the total volume of CBCT, a lateral image is obtained, using the cursor the volume is obtained in an appropriate position; that is, with the Frankfurt plane parallel to the floor, exact matches of the right and left sides (whenever possible) to avoid double contouring. To facilitate visualization and placement of anatomical points, contrast and brightness were adjusted; all the images included a millimeter used to calibrate the image when entering it to the NemoCeph software. Once in an ideal position, the save option was pressed and the software automatically created a lateral image, which was exported in JPEG format. (Figure 2)

The NemoCeph software (Nemotec, Madrid, Spain 2017) with Windows operating system was used to perform the cephalometric analysis; the digital images, the radiography and the cephalogram were selected one by one and calibration was started, digitizing two points in the ruler inside the image (10mm were measured). The Steiner type of analysis to perform was selected, drawing 14 measurements including both angular and linear measurements. (Table 1) When drawing a line the software indicates the point to be used from beginning to end, with the option of fine adjustment to points and curves, which can be moved as convenient. Once done, the trace is finished the software automatically generates the measurements, and data for each analysis were exported in PDF format. Fifteen days after the first evaluation, the points were

redrawn by the same examiner (main evaluator), 4 analyzes were obtained for each patient, 160 in total.

**Statistical analysis**

Data normality was evaluated using the Shapiro Wilk test. After verifying that most do not have a normal distribution, it was decided to analyze the differences between measurements using the nonparametric Wilcoxon signed-rank test for repeated measurements.

Statistical significance was set at  $p < 0.05$ . The Spearman

nonparametric test was used to evaluate the correlation between the variables.

**Ethical aspects**

Both the radiographs and tomography images were used without specific consent for the study because they were imaging studies that were taken in the past, as this was a retrospective study, but consent to undergo the imaging study and probable use in research had been previously obtained.

**Table 1.** Steiner's cephalometric analysis.

Measurements		Definitions
Angular	SNA	The angle formed by the planes Silla-Nasion (S-N) and Nasion-Punto A (N-A).
	SNB	The angle formed by the planes Silla-Nasion (S-N) and Nasion-Punto B (N-B).
	ANB	The angle formed by the planes Nasion Punto A (N-A) and Nasion-Punto B (N-B).
	SND	The angle formed by the planes Silla-Nasion (S-N) and Nasion-Punto D (N-D).
	Occlusal plane angle SN	The angle formed by the occlusal plane and the S-N plane.
	Mandibular plane angle SN	The angle formed by the mandibular plane (Go-Gn) and the S-N plane.
	Interincisal angle	The angle formed by the longitudinal axis of the upper and lower incisors.
	UI NA Angle LI NB Angle	The angle formed by the longitudinal axis of the upper incisor and the N-A plane. The angle formed by the longitudinal axis of the lower incisor and the N-B plane.
Linear measurements	SE Segment	The distance between the Silla point and the L point (S-L). The point L is obtained by drawing a line perpendicular to the plane S-N that intersects Pg.
	SL Segment	The distance between the Silla point and the E point (S-E). Point E is obtained by drawing a line perpendicular to the S-N plane that passes through the most posterior contour of the mandibular condyle (C1).
	UI NA Distance	It is the distance between the incisal edge of the upper incisor and the N-A plane.
	LI NB Distance	The distance between the incisal edge of the lower incisor and the N-B plane.
	Distance Pg to NB	The distance between point Pg and the plane N-B.

**Table 2.** Mean differences between the first and second set of measurements in digital lateral radiographs.

Variables	First Set		Second Set		Comparison		Z	p-value *	
	Mean	SD	Mean	SD	Mean	SD			
Angular measurements	SNA	83.73	4.825	83.75	4.595	0.13	1.399	-590	.555
	SNB	82.63	6.841	82.83	6.774	0.05	1.197	-.346	.730
	ANB	0.95	5.368	1.05	5.301	0	1.261	-.149	.881
	SND	80.05	7.035	80.2	7.094	0.2	1.018	-1409	.159
	Occlusal plane angle SN	16.65	6.041	16.73	5.657	0.03	1.31	-.150	.880
	Mandibular plane angle SN	35.43	7.407	35.08	7.332	0.2	1.305	-.854	.393
	Interincisal angle	135.1	12.85	134.55	13.206	0.45	4.652	-.645	.519
	UI NA Angle LI NB Angle	20.25 23.5	6.994 9.126	20.15 24.23	7.333 9.088	0.43 0.13	3.241 3.04	-1146 -.413	.252 .680
Linear measurements	Distance SE	16.74	2.996	17.17	3.196	0.16	1.217	-.154	.878
	Distance SL	49.733	14.7016	50.005	14.7135	0.16	2.025	-.998	.318
	UI NA Distance	5.08	2.659	4.99	2.637	0.12	1.5	-.619	.536
	LI NB Distance	6.46	3.737	6.46	3.68	0.01	0.681	-.174	.862
	Distance Pg to NB	-0.19	2.663	-0.05	2.428	-0.14	0.739	-2030	.042*

\*: Wilcoxon signed rank test (statistical significance  $p < 0.05$ ). SD: Standard deviation

**Table 3.** Mean differences between the first and second sets of measurements in CBCT virtual cephalogram.

Variables		First Set		Second Set		Comparison		Z	p-value
		Mean	SD	Mean	Mean	SD	DE		
Angular measurements	SNA	84.88	4.603	84.75	4.845	0.03	1.31	-0.79	.937
	SNB	83.53	6.771	83.48	6.679	0.2	0.992	-1208	.227
	ANB	1.33	5.604	1.33	5.327	0.1	1.033	-.651	.515
	SND	80.73	7.247	80.93	7.022	0.15	0.921	-1044	.297
	Occlusal plane angle SN	16.58	5.377	16.6	5.222	0.08	1.716	-.167	.867
	Mandibular plane angle SN	35.55	7.211	35.35	6.841	0.35	1.528	-1177	.239
	Interincisival angle	135.28	11.771	134.83	12.013	0.55	4.057	-.861	.389
	UI NA Angle	19.1	6.834	19.53	6.235	0.1	3.128	-.054	.957
Linear measurements	LI NB Angle	24.33	9.008	24.45	9.179	0.73	2.428	-1918	.055
	Distance SE	16.63	3.154	21.18	30.602	0.43	1.231	-2314	.021*
	Distance SL	51.165	15.0573	51.328	14.4077	0.27	1.419	-.963	.335
	UI NA Distance	4.75	2.519	4.86	2.234	0.09	1.319	-.440	.660
	LI NB Distance	6.46	3.633	6.47	3.58	0.01	0.538	-.378	.706
	Distance Pg to NB	-0.4	2.801	-0.27	2.879	-0.14	0.545	-1496	.135

\*: Wilcoxon signed rank test (statistical significance  $p < 0.05$ ). SD: Standard deviation

**Table 4.** Mean differences between digital lateral radiography and CBCT virtual cephalogram in the first and second sets of measurements.

Variables		First Set			Second Set		
		Mean	SD	p-value *	Mean	SD	p-value *
Angular measurements	SNA	1.15	1.861	.000*	1	2.038	.005*
	SNB	0.9	1.336	.000*	0.65	1.642	.018*
	ANB	0.38	1.444	.188	0.28	1.358	.291
	SND	0.68	1.207	.002*	0.73	1.617	.010*
	Occlusal plane angle SN	0.08	2.055	.684	0.13	2.388	.786
	Mandibular plane angle SN	0.13	1.453	.638	0.28	2.088	.305
	Interincisival angle	0.18	3.7	.944	0.28	5.552	.706
	UI NA Angle	1.15	3.11	.017*	0.63	4.645	.464
Linear measurements	LI NB Angle	0.83	2.8	.106	0.23	3.355	.410
	Distance SE	0.11	1.651	.226	0.7	1.573	.007*
	Distance SL	1.43	2.396	.001*	1.32	2.989	.009*
	UI NA Distance	0.33	1.73	.525	0.13	1.848	.872
	LI NB Distance	0	0.858	.722	0.02	0.708	.628
	Distance Pg to NB	-0.22	0.688	.098	-0.22	0.857	.176

\*: Wilcoxon signed rank test (statistical significance  $p < 0.05$ ). SD: Standard deviation

## RESULTS.

The first and second set of measurements were compared on digital lateral radiographs; the greatest difference in angular measurements was for the interincisival angle  $0.45^\circ$  without statistically significant differences, the smallest difference was for the angle ANB  $0.00^\circ$ , for linear measurements the greatest difference

was for distance SE and SL, 0.16mm each, without statistical significance and the smallest difference was for position LI NB 0.01mm. The distance Pg-NB had a difference of -0.14mm with statistical significance ( $p \leq 0.042$ ). Table 2

The first and second set of measurements was compared in lateral virtual cephalograms. The greatest

**Table 5.** Non-parametric Spearman correlation for digital lateral radiographs and CBCT virtual cephalogram.

Variables		CV1 x CV2		RL1 x CV1		CV2 x RL2		RL1 x RL2	
		r	p-value	r	p-value	r	p-value	r	p-value
Angular measurements	SNA	0.948	<0.001	0.9	<0.001	0.875	<0.001	0.956	<0.001
	SNB	0.986	<0.001	0.971	<0.001	0.974	<0.001	0.987	<0.001
	ANB	0.969	<0.001	0.947	<0.001	0.957	<0.001	0.976	<0.001
	SND	0.986	<0.001	0.98	<0.001	0.971	<0.001	0.988	<0.001
	Occlusal plane angle SN	0.975	<0.001	0.939	<0.001	0.864	<0.001	0.932	<0.001
	Mandibular plane angle SN	0.979	<0.001	0.965	<0.001	0.935	<0.001	0.965	<0.001
	Interincisival angle	0.922	<0.001	0.959	<0.001	0.879	<0.001	0.931	<0.001
	UI NA Angle	0.863	<0.001	0.918	<0.001	0.769	<0.001	0.899	<0.001
Linear measurements	LI NB Angle	0.942	<0.001	0.956	<0.001	0.917	<0.001	0.929	<0.001
	Distance SE	0.908	<0.001	0.815	<0.001	0.856	<0.001	0.911	<0.001
	Distance SL	0.985	<0.001	0.974	<0.001	0.969	<0.001	0.991	<0.001
	UI NA Distance	0.808	<0.001	0.733	<0.001	0.686	<0.001	0.864	<0.001
	LI NB Distance	0.974	<0.001	0.961	<0.001	0.972	<0.001	0.98	<0.001
	Distance Pg to NB	0.919	<0.001	0.936	<0.001	0.904	<0.001	0.962	<0.001

**SCV1:** virtual cephalogram, first measurement. **SCV2:** virtual cephalogram, second measurement. **RL1:** lateral radiograph, first measurement. **RL2:** lateral radiograph, first measurement.

difference in angular measurements was for angle LI NB 0.73° without statistically significant differences, the smallest difference was for SNA 0.03°; for linear measurements the greatest difference was for SE 0.43mm with statistical significance ( $p \leq 0.021$ ) and the smallest difference was for position LI NB 0.01mm. Table 3

When comparing the first set of measurements between the two imaging techniques, the greatest difference in angular measurements was for SNA and upper incisor angle NA 1.15° and the lowest was for the occlusal plane angle 0.08°. In linear measurements the greatest difference was for the distance SL at 1.43mm and the smallest difference for the position LI NB at 0.00 mm. There was a statistically significant difference for four angular measurements (SNA  $p \leq 0.000$ , SNB  $p \leq 0.000$ , SND  $p \leq 0.002$ , UI NA angle  $p \leq 0.017$ ) and one linear measure (distance SL  $p \leq 0.001$ ). Table 4

When comparing the second set of measurements between the two imaging techniques, the greatest difference in angular measurements was for SNA 1° and the smallest difference for the occlusal plane angle 0.13° in linear measurements the greatest difference was for the SL distance at 1.32mm and the smallest difference was for the position LI NB at 0.02mm.

A statistically significant difference was found for

three angular measurements (SNA  $p \leq 0.005$ , SNB  $p \leq 0.018$ , SND  $p \leq 0.010$ ) and two linear measurements (SE  $p \leq 0.007$ , SL  $p \leq 0.009$ ). Table 4

The Spearman nonparametric test was used to evaluate the correlation between the variables: in the comparison between cephalograms the range varied from 0.863 to 0.986 for angular measurements and from 0.808 to 0.985 for linear measurements; in the comparison between radiographs and cephalograms in the first set of measurements the range varied from 0.900 to 0.971 for angular measurements and 0.733 to 0.974 for linear measurements. In the comparison between radiographs and cephalograms in the second set of measurements, the range varied between 0.769 and 0.974 for angular measurements and 0.686 and 0.972 for linear measurements; and, in the comparison between radiographs, the range varied between 0.899 and 0.988 for angular measurements and 0.864 and 0.991 for linear measurements.

The correlation for most of the variables is greater than 0.9, as can be observed in Table 5, which is excellent, and even though the UI NA angle in the comparison between cephalograms and radiographs in the second set of measurements has the lowest correlation, all reach statistical significance.

## DISCUSSION.

The variations between the two types of images reflect the technical differences inherent in the systems, in terms of obtaining the image.<sup>3</sup> This could explain the results obtained in this study as, when comparing the image techniques separately, the differences were minimal; for radiographs, the difference varied between 0.0° and 0.45° for angular measurements, and between 0.01mm and 0.16mm in linear measurements; in cephalograms, the difference varied between 0.03° and 0.73° for angular measurements, and between 0.01mm and 0.43mm in linear measurements. In turn, if the two imaging techniques are compared with each other, the difference was greater, so that, in the first set of measurements between radiography and cephalogram, the difference varied between 0.08° and 1.15° in angular measurements, and between 0.00mm and 1.43mm in linear measurements; in the second set of measurements between radiography and cephalogram, the difference varied between 0.13° and 1° for angular measurements, and between 0.02mm and 1.32mm in linear measurements. The differences were smaller for the second set of measurements. When comparing the imaging techniques with each other for both the first and second set of measurements, SNA presented statistically significant differences; this could be justified by the difficulty of locating Point A in accordance with Yu *et al.*<sup>13</sup>

The UI NA angle presented statistically significant differences in the first set of measurements between the two types of image, a result in agreement with Wen *et al.*,<sup>14</sup> in conventional lateral radiography it is often difficult to locate the apex of a tooth because the contrast between the apex image and the surrounding tissues is usually poor.<sup>15</sup> In addition, it is difficult to distinguish between central and lateral incisors especially in cases of crowding or when the lateral incisor is more prominent than the central incisors.<sup>16</sup> Dental reference points generally have a lower validity compared to skeletal reference points,<sup>17</sup> But among them point A has a greater variability compared to point B due to a wider variation and to the anatomical location of point A.<sup>18</sup>

The distance SL presented statistically significant differences both in the first and in the second set of

measurements when comparing the two types of image, which can be justified by the difficulty of locating the Pg point (necessary for this measurement), because it is on a curved surface so its location is not so easily reproducible<sup>14</sup> and generally these reference points are more associated with errors,<sup>12</sup> like point C1, which is identified to establish the distance SE, and which also presented statistically significant differences in the second set of measurements when comparing the two types of image. Results that can be compared with others regarding points in curved structures had lower reproducibility; thus, studies in which conventional radiographs were compared with cephalograms generated from CBCT such as Aksoy *et al.*,<sup>19</sup> showed good reproducibility for most measures evaluated except for Co-Gn, Go-Me, SNA-Me, and Wits; Da Silva *et al.*,<sup>20</sup> reported a CCI between 0.969 and 0.999 indicative of high reliability for most measurements except GoGn.SN and IMPA, which involved the Go point, and the linear measurements that involved the lips which presented a significant difference. The Pg to NB distance present a statistically significant difference when comparing the first and second set of measurements in radiographs, which could also be justified as stated by Tng *et al.*,<sup>21</sup> that when the reference points are located in a curve such as point A, point B or Pg, the error is greater.

The difference between the two types of image was minimal, which means that measurements generated from CBCT cephalograms are comparable to conventional ones. The adequate reproducibility can be due to the possibility of moving the volume of CBCT to a suitable position, where the right and left sides can be adjusted until they match and an ideal image is obtained, which is an option for virtual cephalogram generated by the Planmeca Romexis equipment.

Besides the software tools that allow to improve brightness and contrast and aid in locating the points; also in the digital lateral radiography nowadays and with the modern equipments available in the market, it is possible to improve the image so that the anatomical points are easier to identify. However, the projection errors inherent in the conventional technique can make it difficult to locate the points.<sup>22</sup> It must be emphasized that not all patients should undergo CBCT scans; only

those who, after a thorough evaluation, the benefits of CBCT images outweigh those of images obtained with conventional techniques. As such all the images used in this study correspond to surgical patients with maxillofacial alterations of medium and high grade, clinically justifying undergoing CBCT imaging.

Results obtained in this study agree with several others who also compared conventional cephalograms with those generated from CBCT and obtained an adequate reproducibility for both, such as Aksoy *et al.*,<sup>19</sup> Da Silva *et al.*,<sup>20</sup> Cattaneo *et al.*,<sup>22</sup> Hariharan *et al.*,<sup>23</sup> Cassetta *et al.*,<sup>24</sup> Zamora *et al.*,<sup>25</sup> among other. Nevertheless better accuracy for cephalograms obtained from CBCT was emphasized by Shokri *et al.*,<sup>26</sup> who used dry skulls, the gold standard for measurements, and their results showed that the values obtained in CBCT cephalograms were much closer to the real measurements, and also mentioned it would be desirable that the diagnosis in orthodontics and treatment planning is based on CBCT scans, especially when decisions depend on precise linear measurements such as orthognathic surgery. Navarro *et al.*,<sup>3</sup> also reports a better reproducibility for CBCT cephalograms because in their study there were no statistically significant differences between the first and second observations, unlike the other two methods used (manual tracing and digital lateral cephalogram); as such so the authors mention that the strokes are more reliable. Van Vlijmen *et al.*,<sup>27</sup> note that the reproducibility of measurements in cephalograms generated from CBCT was better than conventional ones.

There were no clinically relevant differences between the two image types, therefore, cephalograms generated from CBCT are adequate for longitudinal follow-up in patients who have 2D and 3D records. Furthermore digital layout has the following advantages: excellent reproducibility, time saved by avoiding layout and efficiency, as no additional equipment is necessary.<sup>13</sup> Although in our study the computerized analysis was carried out only using the NemoCeph software, there are other studies that have compared different types of software such as *in vivo* 5.1.2, Maxilim and Romexis in the study by Aksoy *et al.*,<sup>19</sup> with similar results and good reproducibility in most measures evaluated. Zamora

*et al.*,<sup>25</sup> compared the NemoCeph 3D and *in vivo* 5.1.2, reporting no statistically significant differences between angular or linear measurements using the two software packages. It would be ideal to carry out more comparative studies using other types of software. Previous studies<sup>7,8,28,29</sup> have indicated that differences of up to 2° or 2mm do not represent clinical relevance (in the present study the range of difference was much smaller). However, the accuracy is important, as errors in image visualization would result in altered diagnoses and therefore in erroneous treatment plans.<sup>30</sup>

Wen *et al.*,<sup>14</sup> point out two important points regarding the cephalogram generated by CBCT: first, the advantage that cephalograms would be an alternative to conventional lateral radiography for patients with already available CBCT scans minimizing patient exposure to radiation and costs for radiography; second the disadvantage that cephalograms may not add value for each orthodontic case, and additional exposure is not necessary if the images are simply collapsed to produce a 2D image from which to work.

It should also be considered that to obtain a cephalogram from CBCT the field of vision to be used is the largest, so that structures such as S, N, dentition and the maxilla can be visualized, which requires exposure to a dose between 68 to 368mSv, higher than for a digital lateral radiograph that requires a dose of approximately 30mSv.<sup>31</sup> While there are several protocols and authors who have made available guidelines and recommendations on the use of CBCT in certain circumstances<sup>32,33</sup> and that this imaging technique is also beneficial for patients with maxillofacial deformities (cleft palate and severe asymmetric deformity) and for those who require orthognathic surgery,<sup>34</sup> the decision is finally made by the clinician according to each specific case, always considering that the benefits must outweigh the risks. This is true especially regarding children and young adults, in whom the selection of an imaging study should be based on the patient's history, the clinical examination, the available images and the presence or absence of a clinical condition.<sup>5</sup>

For this reason, justifying a CBCT exploration is of uttermost importance, as illustrated by Kapila *et al.*,<sup>35</sup> "The justification for using CBCT in orthodontics is linked



*intricately to its diagnostic and therapeutic efficacies”* who have classified the use of CBCT into three categories based on the information from current scientific evidence, as such: indicated, positive benefit-proportional to risk, and not indicated. The authors also add that CBCT has not shown clinical utility in all types of cases.

## REFERENCES.

1. Broadbent BH. A new x-ray technique and its application to orthodontia. *Angle Orthod.* 1981;51:93-114.
2. Souza KR, Oltramari-Navarro PV, Navarro Rde L, Conti AC, Almeida MR. Reliability of a method to conduct upper airway analysis in cone-beam computed tomography. *Braz Oral Res.* 2013;27(1):48-54.
3. Navarro Rde L, Oltramari-Navarro PV, Fernandes TM, Oliveira GF, Conti AC, Almeida MR, Almeida RR. Comparison of manual, digital and lateral CBCT cephalometric analyses. *J Appl Oral Sci.* 2013;21(2):167-76.
4. Baumrind S, Frantz RC. The reliability of head film measurements. I. Landmark identification. *Am J Orthod.* 1971;60(2):111-27.
5. Pittayapat P, Bornstein MM, Imada TS, Coucke W, Lambrechts I, Jacobs R. Accuracy of linear measurements using three imaging modalities: two lateral cephalograms and one 3D model from CBCT data. *Eur J Orthod.* 2015;37(2):202-8.
6. Thurzo A, Javorka V, Stanko P, Lysy J, Suchancova B, Lehotska V, Valkovic L, Makovnik M. Digital and manual cephalometric analysis. *Bratisl Lek Listy.* 2010;111(2):97-100.
7. Naoumova J, Lindman R. A comparison of manual traced images and corresponding scanned radiographs digitally traced. *Eur J Orthod.* 2009;31(3):247-53.
8. Chen YJ, Chen SK, Yao JC, Chang HF. The effects of differences in landmark identification on the cephalometric measurements in traditional versus digitized cephalometry. *Angle Orthod.* 2004;74(2):155-61.
9. Kusnoto B. Two-dimensional cephalometry and computerized orthognathic surgical treatment planning. *Clin Plast Surg.* 2007;34(3):417-26.
10. Leonardi R, Giordano D, Maiorana F, Spampinato C. Automatic cephalometric analysis. *Angle Orthod.* 2008;78(1):145-51.
11. van Vlijmen OJ, Maal TJ, Bergé SJ, Bronkhorst EM, Katsaros C, Kuijpers-Jagtman AM. A comparison between two-dimensional and three-dimensional cephalometry on frontal radiographs and on cone beam computed tomography scans of human skulls. *Eur J Oral Sci.* 2009;117(3):300-5.
12. Tan SS, Ahmad S, Moles DR, Cunningham SJ. Picture archiving and communications systems: a study of reliability of orthodontic cephalometric analysis. *Eur J Orthod.* 2011;33(5):537-43.
13. Yu SH, Nahm DS, Baek SH. Reliability of landmark identification on monitor-displayed lateral cephalometric images. *Am J Orthod Dentofacial Orthop.* 2008;133(6):e1-6.
14. Wen J, Liu S, Ye X, Xie X, Li J, Li H, Mei L. Comparative study of cephalometric measurements using 3 imaging modalities. *J Am Dent Assoc.* 2017;148(12):913-21.
15. Stabrun AE, Danielsen K. Precision in cephalometric landmark identification. *Eur J Orthod.* 1982;4(3):185-96.
16. Chan CK, Tng TH, Hägg U, Cooke MS. Effects of cephalometric landmark validity on incisor angulation. *Am J Orthod Dentofacial Orthop.* 1994;106(5):487-95.
17. Durão AR, Pittayapat P, Rockenbach MI, Olszewski R, Ng

## CONCLUSION.

The difference between the two types of image is minimal. The methods evaluated can be used effectively, always using the best clinical criteria when prescribing X-rays and even more importantly when ordering CBCT scans, in order to use the lowest possible dose of ionizing radiation.

- S, Ferreira AP, Jacobs R. Validity of 2D lateral cephalometry in orthodontics: a systematic review. *Prog Orthod.* 2013;14:31.
18. Houston WJ, Maher RE, McElroy D, Sherriff M. Sources of error in measurements from cephalometric radiographs. *Eur J Orthod.* 1986;8(3):149-51.
19. Aksoy S, Kelahmet U, Hincal E, Oz U, Orhan K. Comparison of linear and angular measurements in CBCT scans using 2D and 3D rendering software. *Int J Artif Organs.* 2016;30(4):777-84.
20. da Silva MB, Gois BC, Sant'Anna EF. Evaluation of the reliability of measurements in cephalograms generated from cone beam computed tomography. *Dental Press J Orthod.* 2013;18(4):53-60.
21. Tng TT, Chan TC, Hägg U, Cooke MS. Validity of cephalometric landmarks. An experimental study on human skulls. *Eur J Orthod.* 1994;16(2):110-20.
22. Cattaneo PM, Bloch CB, Calmar D, Hjortshøj M, Melsen B. Comparison between conventional and cone-beam computed tomography-generated cephalograms. *Am J Orthod Dentofacial Orthop.* 2008;134(6):798-802.
23. Hariharan A, Diwakar NR, Jayanthi K, Hema HM, Deepukrishna S, Ghaste SR. The reliability of cephalometric measurements in oral and maxillofacial imaging: Cone beam computed tomography versus two-dimensional digital cephalograms. *Indian J Dent Res.* 2016;27(4):370-7.
24. Cassetta M, Altieri F, Di Giorgio R, Silvestri A. Two-Dimensional and Three-Dimensional Cephalometry Using Cone Beam Computed Tomography Scans. *J Craniofac Surg.* 2015;26(4):e311-5.
25. Zamora N, Llamas JM, Cibrián R, Gandia JL, Paredes V. Cephalometric measurements from 3D reconstructed images compared with conventional 2D images. *Angle Orthod.* 2011;81(5):856-64.
26. Shokri A, Khajeh S, Khavid A. Evaluation of the accuracy of linear measurements on lateral cephalograms obtained from cone-beam computed tomography scans with digital lateral cephalometric radiography: an in vitro study. *J Craniofac Surg.* 2014;25(5):1710-3.
27. van Vlijmen OJ, Bergé SJ, Swennen GR, Bronkhorst EM, Katsaros C, Kuijpers-Jagtman AM. Comparison of cephalometric radiographs obtained from cone-beam computed tomography scans and conventional radiographs. *J Oral Maxillofac Surg.* 2009;67(1):92-7.
28. Kumar V, Ludlow J, Soares Cevidanes LH, Mol A. In vivo comparison of conventional and cone beam CT synthesized cephalograms. *Angle Orthod.* 2008;78(5):873-9.
29. Cavalcanti MG, Haller JW, Vannier MW. Three-dimensional computed tomography landmark measurement in craniofacial surgical planning: experimental validation in vitro. *J Oral Maxillofac Surg.* 1999;57(6):690-4.
30. Yitschaky O, Redlich M, Abed Y, Faerman M, Casap N, Hiller N. Comparison of common hard tissue cephalometric measurements between computed tomography 3D reconstruction and conventional 2D cephalometric images. *Angle Orthod.* 2011;81(1):11-6.
31. Pauwels R, Beinsberger J, Collaert B, Theodorakou C, Rogers

J, Walker A, Cockmartin L, Bosmans H, Jacobs R, Bogaerts R, Horner K, SEDENTEXCT Project Consortium. Effective dose range for dental cone beam computed tomography scanners. *Eur J Radiol.* 2012;81(2):267–71.

32. Isaacson KG, Thom AR, Atack NE, Horner K, Whaites E. *Orthodontic Radiographs: Guidelines for the Use of Radiographs in Clinical Orthodontics.* 4th Ed. London, England: British Orthodontic Society; 2015.

33. Horner K, Panel SEDENTEXCT. Cone Beam CT for Dental

and Maxillofacial Radiology (Evidence Based Guidelines), (Radiation Protection series). Luxembourg: European Commission: Directorate-General for Energy; 2012.

34. Noffke CE, Farman AG, Nel S, Nzima N. Guidelines for the safe use of dental and maxillofacial CBCT: a review with recommendations for South Africa. *SADJ.* 2011;66(6):262–6.

35. Kapila SD, Nervina JM. CBCT in orthodontics: assessment of treatment outcomes and indications for its use. *Dentomaxillofac Radiol.* 2015; 44: 20140282.